

REVIEW ARTICLE

MEDICAL PROGRESS

Soft-Tissue Sarcomas in Adults

Matthew A. Clark, F.R.A.C.S., Cyril Fisher, F.R.C.Path., Ian Judson, F.R.C.P.,
and J. Meirion Thomas, F.R.C.S.

SOFT-TISSUE SARCOMAS ARE UNCOMMON TUMORS THAT HAVE TRADITIONALLY been managed by wide excisional surgery and radiotherapy; the use of chemotherapy has been reserved for advanced disease. Advances in multidisciplinary care have improved the evaluation and care of patients with this disease. Limb-conserving surgical paradigms, superior radiotherapy delivery, and novel adjuvant agents for specific tumors are now available. This overview is intended as a review of current understanding and treatment of soft-tissue sarcoma, with an emphasis on recent advances.

Although soft-tissue sarcomas can arise anywhere in the body (Table 1), the majority occur in the limb or limb girdle or within the abdomen (retroperitoneal or visceral and intraperitoneal). Benign soft-tissue tumors, especially lipomas, are 100 times as common. Soft tissue in this context is defined as nonepithelial extraskeletal tissue, including muscle, fat, and fibrous supporting structures, arising mainly from embryonic mesoderm, with some neuroectodermal contribution.

Accurate pretreatment evaluation is critical for treating soft-tissue sarcomas. Surgery for localized disease is often curative, alone or in combination with radiotherapy and chemotherapy in selected patients. Function-preserving limb conservation is the goal of treatment for soft-tissue sarcomas of the limbs. Intraabdominal tumors pose treatment challenges because of the proximity of adjacent vital organs. Half of patients with soft-tissue sarcomas will die from this disease, a statistic that has changed little in recent decades.¹

Soft-tissue sarcomas are best treated in multidisciplinary centers that specialize in treating this disease,²⁻⁶ have experience with functional limb preservation, and have low rates of local recurrence and good rates of overall survival.³ The management of this tumor at other types of centers may lead to inappropriate tests,² positive margins after surgical resection, and a reduced likelihood of radiotherapy.⁶ Patients with soft-tissue sarcomas are reportedly willing to travel greater distances in order to receive care in a specialty center.⁴ Specialists who preserve the function of a given site can work cooperatively with oncologists to enhance the likelihood of a good outcome.

DEMOGRAPHIC AND ETIOLOGIC CHARACTERISTICS

Soft-tissue sarcomas account for only about 1 percent of all cancers.⁷ Approximately 8700 new cases of soft-tissue sarcoma are diagnosed each year in the United States⁷ and about 1500 in the United Kingdom. The relative frequency and response of each subtype vary according to age. For example, soft-tissue sarcomas in children, particularly rhabdomyosarcomas, more often respond to chemotherapy than do those in adults.⁸ The overall incidence of soft-tissue sarcoma has been increasing,⁹ perhaps as a result of the increase in Kaposi's sarcoma, which is often associated with the acquired immunodeficiency syndrome (AIDS),^{9,10} as well as improved recognition and diagnosis.

Most soft-tissue sarcomas are sporadic; few have an identifiable cause. There is an association between certain viral infections (notably Epstein-Barr virus in those with AIDS) and leiomyosarcoma.¹¹ Sarcoma may develop 3 to 15 years after therapeutic ir-

From the Sarcoma Unit, the Royal Marsden Hospital National Health Service Foundation Trust, London. Address reprint requests to Mr. Clark at the Department of General Surgery, Middlemore Hospital, P.O. Box 93311 Otahuhu, Auckland, New Zealand, or at sarcoma@mac.com.

N Engl J Med 2005;353:701-11.

Copyright © 2005 Massachusetts Medical Society.

Table 1. Distribution of Soft-Tissue Sarcoma.*

Site	Incidence
	%
Lower limb and girdle	40
Upper limb and girdle	20
Retroperitoneal and intraperitoneal sites†	20
Trunk	10
Head and neck	10

* Percentages are approximate.

† These sites include gastrointestinal stromal tumors.

radiation for lymphoma, cervical cancer, testicular tumor, or breast cancer. However, the benefits of radiotherapy in such circumstances outweigh the minimally increased¹² risk of sarcoma. Chronic lymphedema-associated angiosarcoma (Stewart-Treves syndrome) usually occurs as a rare complication of treatment for breast cancer. Some genetic disorders are associated with soft-tissue sarcomas. For example, neurofibromatosis type 1 carries a 10 percent lifetime risk of malignant tumors of the peripheral-nerve sheath. Children with hereditary retinoblastoma (owing to a germ-line mutation in the *RB1* tumor-suppressor gene) face an exceptionally high risk of osteosarcoma and soft-tissue sarcoma, which is further increased by the receipt of radiotherapy.¹³ Sarcoma has also been reported in patients with the Li-Fraumeni syndrome, which is caused by a germ-line mutation in the *p53* tumor-suppressor gene.¹⁴

CLINICAL FEATURES, ROLE OF IMAGING, AND DIAGNOSIS

The clinical symptoms accompanying the diagnosis of soft-tissue sarcoma are nonspecific. The most common finding at presentation is a painless, gradually enlarging mass. The size of the tumor at diagnosis varies according to the site; tumors of the distal limbs and head or neck are usually smaller because they are likely to be noticed earlier, whereas tumors of the thigh and retroperitoneum may become huge before they are detected. Soft-tissue sarcomas expand in a spherical fashion but infiltrate the tumor pseudocapsule and, occasionally, adjacent structures. Accordingly, patients with these tumors may present with site-dependent symptoms of increased pressure, such as paresthesia, distal edema, or bladder symptoms.

The growth rate of soft-tissue sarcomas varies with the aggressiveness of the tumor. Low-grade tumors may evolve over a long period and may be mistaken for benign tumors, especially lipomas. Such a mistake may delay referral to a specialist center.¹⁵ Indeed, the identification of soft-tissue sarcoma relies on clinical examination, imaging, and histologic analysis. Examination and imaging can be used to define the tumor's relationship to surrounding structures.

Plain radiographs may be used to rule out bone neoplasms and detect calcifications characteristic of soft-tissue osteosarcoma or synovial sarcoma. A chest radiograph is essential, though preoperative computed tomography (CT) of the thorax is preferable for detecting metastases. CT and magnetic resonance imaging (MRI) are used to image the primary tumor; neither offers an overall advantage.¹⁶ CT is usually performed to identify intraabdominal tumors, such as liposarcoma, the most common retroperitoneal tumor. The multiplanar images and better anatomical definition possible with the use of MRI are its key advantages; this approach is preferred for the diagnosis of soft-tissue sarcoma of the limbs. Advances in these two approaches now permit faster acquisition of images and better spatial resolution.¹⁷ Dynamic gadolinium-enhanced MRI can be used to identify early enhancement of viable tumor tissue as compared with surrounding reactive tissues. Additional imaging approaches offer future promise. A recent meta-analysis of the results of positron-emission tomography (PET) with fludeoxyglucose F 18 concluded that routine use is currently unjustified.¹⁸ Combining functional information obtained from PET with anatomical detail from CT¹⁹ or MRI²⁰ may increase the usefulness of these techniques. Magnetic resonance spectroscopy may be useful in some circumstances, such as when one is assessing a patient's response to chemotherapy when resection has not been performed.²¹

With few exceptions, histologic examination of a tumor specimen is required before treatment is initiated. Percutaneous core needle biopsy is safe and effective^{22,23} and can be performed with the use of local anesthesia on an outpatient basis for palpable tumors of the arms and legs. The biopsy site should be chosen so that it will lie within the area of a possible subsequent en bloc resection of the tumor. The subtype and grade of the tumor can be determined in 80 percent of core needle biopsies,^{22,23} and pathologists experienced in examining soft-tis-

sue sarcomas have a diagnostic accuracy of 95 to 99 percent. So-called small round-cell tumors (embryonal rhabdomyosarcoma, Ewing's sarcomas, and lymphoma) can be identified by needle biopsies, permitting nonsurgical induction therapy (Fig. 1). Currently, incisional biopsy is less common than needle biopsy at many centers. In the hands of a nonexpert, incisional biopsies have a higher rate of complications than core needle biopsies² and thus should be performed only in exceptional circumstances, ideally by the surgeon planning the definitive resection. Cytologic analysis of fine-needle aspirates alone can be used to diagnose recurrent tumor²⁴ or nodal metastases. Regardless of how biopsy material is obtained, the specimen is best evaluated by a pathologist specializing in soft-tissue diseases.^{2,25}

If imaging suggests that a retroperitoneal tumor is most likely a resectable soft-tissue sarcoma (Fig. 2), biopsy should not be performed, given the potential for transperitoneal spread and track implantation.²⁶ Exceptions include suspected lymphoma or germ-cell tumors, which usually appear as paracaval or paraaortic masses on CT, and masses tentatively identified as sarcomas for which preoperative chemotherapy or radiotherapy is contemplated. A biopsy should be considered if a gastrointestinal stromal tumor is suspected on radiologic grounds,²⁷ if metastatic disease is suspected, or if the tumor is unresectable.

PATHOLOGICAL FEATURES

The World Health Organization²⁸ has defined approximately 50 tumor subtypes relevant to soft-tissue sarcomas; these are named largely according to the tissue they most closely resemble. A three-step grading system devised by the French Federation of Cancer Centers Sarcoma Group²⁹ is widely used and takes into account the degree of differentiation, the mitotic count, and the extent of necrosis. Four-step grading systems are also in use.³⁰ It is difficult to grade tumors previously treated with radiotherapy or chemotherapy and recurrent tumors.

Determining the stage of a tumor allows physicians to estimate the prognosis. The staging system devised by the American Joint Committee on Cancer (AJCC) and the International Union against Cancer (UICC) (Fig. 3)³⁰ combines the most important determinants of survival in localized soft-tissue sarcomas of the limbs: the grade, depth, and size of the tumor. Large series confirm that grade and size are

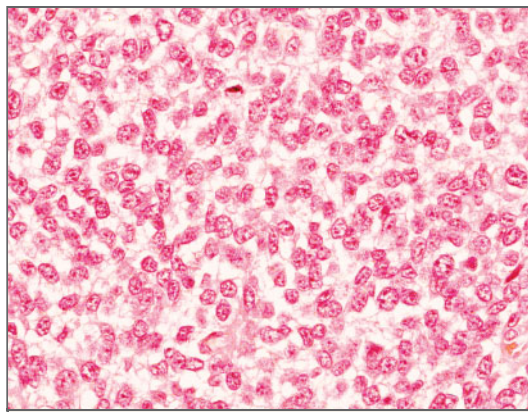


Figure 1. Photomicrograph of Ewing's Sarcoma, a Type of Small Round-Cell Tumor (Hematoxylin and Eosin).

Small round-cell tumors can be diagnosed with the use of core needle biopsy, making possible the initiation of appropriate therapy.

of similar prognostic importance.^{31,32} Five-year survival rates for stages I, II, III, and IV are approximately 90, 70, 50, and 10 to 20 percent, respectively, and are further modified by the type and site of the tumor and other factors.³³ Prognostic algorithms derived from large databases can be used to provide longer-term survival estimates.³⁴

The use of conventional staging systems for retroperitoneal tumors is less accurate prognostically, but a method based on grade, the completeness of resection, and the presence or absence of metastases can be used to identify groups with different outcomes.⁵ Other risk factors are relevant to certain tumors; for example, tumor size and mitotic count are used to assess risk in cases of localized gastrointestinal stromal tumors.³⁵

The classification and characterization of soft-tissue sarcomas have evolved as the information supplied by histologic analysis has been supplemented with that provided by immunohistochemical analysis and with an improved understanding of the underlying genetic changes. Identification techniques are increasingly applicable to formalin-fixed, paraffin-embedded material. Genetic aberrations have been described in many soft-tissue tumors and help identify tumors that were previously difficult to classify, especially pleomorphic soft-tissue sarcomas.³⁶ Aberrations can be hereditary or acquired.^{14,37-39} Consistent, specific translocations resulting in new fusion genes characterize some sarcomas (Table 2). Genetic information can facilitate the diagnosis (especially in the case of small

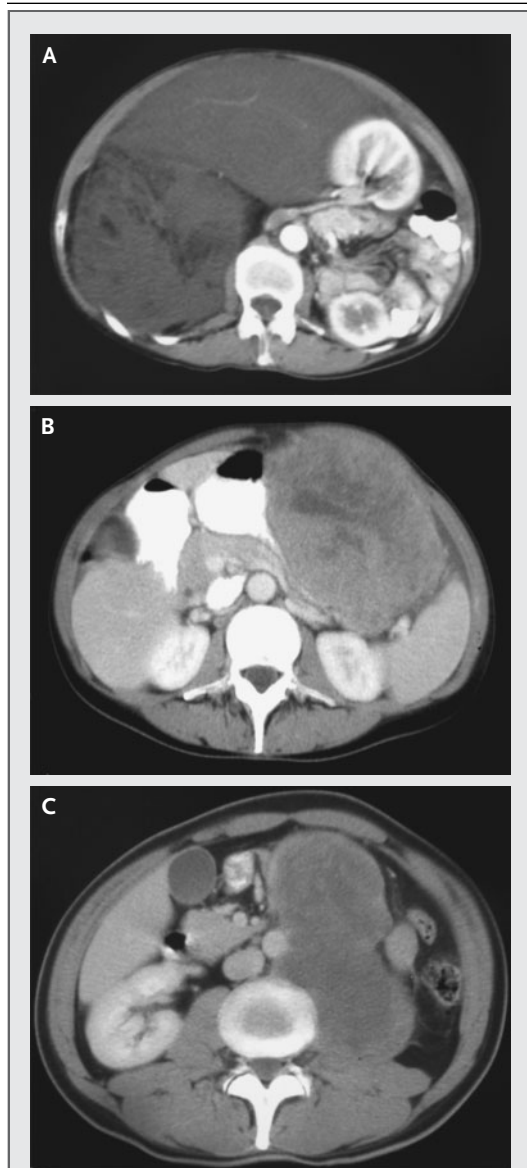


Figure 2. CT Scans of Large Retroperitoneal Masses Suggestive of Soft-Tissue Sarcoma.

Panel A shows a liposarcoma with characteristic features. The tumor has caused the right kidney to rotate and overlie the left kidney. Panel B shows a huge mass of borderline resectability. Percutaneous core needle biopsy confirmed the diagnosis of gastrointestinal stromal tumor, and imatinib therapy was initiated. Panel C shows an unresectable mass in psoas muscle; the aorta is displaced. Core needle biopsy revealed a malignant germ-cell tumor treatable with chemotherapy. Levels of tumor markers were elevated, and ultrasonography showed that the left testis was abnormal.

round-cell tumors), confirm relationships between morphologic subtypes, and predict the behavior of specific sarcomas beyond that provided by the general features of grade, size, and depth.⁴⁰ One emerging application is mutational analysis of gastrointestinal stromal tumors, in which mutations in the *KIT* gene appear to have a major effect on treatment response and survival.⁴¹ Emerging gene-array and proteomic techniques are being applied to identify potential treatment targets, which may help to individualize therapy.^{42,43}

TREATMENT

Surgery — supplemented when necessary by adjuvant radiotherapy — is often curative for localized soft-tissue sarcomas. As already discussed, treatment is best planned in a multidisciplinary setting, which facilitates consideration of the need for pre-operative induction treatment, discussion of reconstructive strategies, and planning for rehabilitation. This assessment should include histologic review by an expert on soft-tissue sarcoma to verify or alter the classification or grade of the tumor²⁵; a change in the grade or class may necessitate a change in the treatment plan.

Although local treatment of primary soft-tissue sarcoma of the limbs influences the likelihood of local recurrence, limb salvage, and functional outcome, the metastatic potential is mainly determined by the grade and size of the primary tumor. There is little evidence that local recurrence increases the likelihood of metastatic spread, although debate on this point continues.^{32,44} Except for rhabdomyosarcomas and Ewing's sarcomas, the use of adjuvant chemotherapy generally does little to influence the natural history of the disease.

SURGERY

Surgical resection involving wide margins, with or without radiotherapy, offers the best chance of cure in the absence of metastatic disease. The operation should be planned by an experienced surgical team after careful study of the scans. Because soft-tissue sarcoma can occur at any site, every operation will be different, though common surgical oncologic principles prevail.

Because soft-tissue sarcomas expand spherically and along tissue planes, their centrifugal growth creates a false capsule, or pseudocapsule, of com-

Grade and TNM	Description	Stage			
		T1a	T1b	T2a	T2b
G1	Well differentiated				
G2	Moderately differentiated				
G3	Poorly differentiated				
G4	Undifferentiated				
T1	Tumor ≤5 cm in largest dimension				
T1a	Superficial to deep fascia				
T1b	Deep to deep fascia (includes retroperitoneal, intrathoracic, and most head and neck tumors)				
T2	Tumor >5 cm in largest dimension				
T2a	Superficial to deep fascia				
T2b	Deep to deep fascia (includes retroperitoneal, intrathoracic, and most head and neck tumors)				
N1	Regional nodal metastasis				
M1	Distant metastasis				

5-Yr Survival	
Stage	%
I	86
II	72
III	52
IV	10–20

Figure 3. Descriptions of Stages, Grades, and the Tumor–Node–Metastasis (TNM) System of the American Joint Committee on Cancer for Soft-Tissue Sarcoma and the International Union against Cancer.
Data have been modified from Greene et al.³⁰

pressed surrounding tissue. Malignant cells penetrate this pseudocapsule.⁴⁵ Simple removal of visible tumor in this plane leaves microscopic disease in situ, and 90 percent of tumors recur unless there is further treatment. Over 30 percent will recur even after further excision of the tumor bed,⁴⁶ and the subsequent use of radiotherapy does not compensate for the presence of unplanned positive histologic margins.⁴⁷ (In contrast, leaving a carefully considered positive margin adjacent to a critical structure to facilitate limb preservation results in rates of local recurrence of only approximately 4 percent when planned irradiation is carried out.⁴⁶) Thus, the goal of surgery is to resect the tumor with wide (2 to 3 cm) margins when possible, removing at least one uninvolved tissue plane circumferentially.

Approximately one third of patients with a low- or intermediate-grade tumor and wide resection margins will not require further treatment (including radiotherapy). It is rarely necessary to reconstruct major vessels or to resect major nerves unless they are encased by tumor. However, resection of some major nerves generally results in surprisingly little disability; therefore, resection should be considered if amputation is the alternative.⁴⁸ If it is safe from an oncologic perspective, preserving one innervated muscle in any compartment results in

better function than a more radical approach.⁴⁹ Although tumors are usually smaller in the distal limbs than in the proximal limbs, it is more difficult to preserve function in the distal limbs, especially the forearms and hands. Preoperative induction treatment may reduce the size of tumors of distal limbs and facilitate better functional results.

Amputation is ultimately required in 5 to 10 percent of patients with sarcoma of the limbs, usually after previous limb-salvage operations.⁵⁰ In such cases, major amputations (forequarter, hindquarter, or through-hip amputation) are often necessary, because recurrences are generally proximal. Such procedures are tolerated remarkably well and provide excellent local control.⁵¹

The skin is rarely involved in soft-tissue sarcoma and can usually be preserved. Skin and soft-tissue reconstruction is required in 10 to 20 percent of patients and can reduce complications or avert amputation, especially in the case of recurrences in previously irradiated locations. Transposed myocutaneous or fasciocutaneous flaps are commonly used, but it is sometimes necessary to transfer free tissue. In selected cases, early involvement of surgeons with expertise in reconstructive surgery optimizes functional and cosmetic results⁵² while preserving reconstruction options. Site- and organ-specific lesions are often managed with the help

Table 2. Chromosomal Translocations in Soft-Tissue Sarcomas.*

Type of Tumor	Translocation	Genes Involved
Synovial sarcoma	t(X;18)(p11.2;q11.2)	<i>SSX1</i> or <i>SSX2</i> , <i>SYT</i>
Myxoid or round-cell liposarcoma	t(12;16)(q13;p11)	<i>CHOP</i> , <i>TLS</i>
	t(12;22)(q13;q11-q12)	<i>CHOP</i> , <i>EWS</i>
Ewing's sarcoma or peripheral primitive neuroectodermal tumor	t(11;22)(q24;q12)	<i>FLI1</i> , <i>EWS</i>
	t(21;22)(q22;q12)	<i>ERG</i> , <i>EWS</i>
	t(7;22)(p22;q12)	<i>ETV1</i> , <i>EWS</i>
	t(2;22)(q33;q12)	<i>FEV</i> , <i>EWS</i>
	t(17;22)(q12;q12)	<i>E1AF</i> , <i>EWS</i>
Desmoplastic small round-cell tumor	t(11;22)(p13;q12)	<i>WT1</i> , <i>EWS</i>
Alveolar rhabdomyosarcoma	t(2;13)(q35;q14)	<i>PAX3</i> , <i>FKHR</i>
	t(1;13)(p36;q14)	<i>PAX7</i> , <i>FKHR</i>
Extraskeletal myxoid chondrosarcoma	t(9;22)(q21-31;q12.2)	<i>CHN</i> , <i>EWS</i>
	t(9;17)(q22;q11)	<i>CHN</i> , <i>RBP56</i>
Clear-cell sarcoma	t(12;22)(q13;q12)	<i>ATF1</i> , <i>EWS</i>
Alveolar soft-part sarcoma	t(X;17)(p11;q25)	<i>TFE3</i> , <i>ASPL</i>
Dermatofibrosarcoma or giant-cell fibroblastoma	t(17;22)(q22;q13)	<i>COL1A1</i> , <i>PDGFB1</i>
Infantile fibrosarcoma	t(12;15)(p13;q25)	<i>ETV6</i> , <i>NTRK3</i>
Low-grade fibromyxoid sarcoma	t(7;16)(q34;p11)	<i>FUS</i> , <i>BBF2H7</i>

* The translocations should be read, for example, as follows: t(X;18)(p11.2;q11.2) is a translocation between chromosomes X and 18 involving the short arm at region 11.2 and the long arm at region 11.2.

of other specialists, including head-and-neck surgeons, gynecologists, and urologists.

Surgery is the mainstay of treatment for soft-tissue sarcomas of the retroperitoneum (15 percent of soft-tissue sarcomas). En bloc resection of adjacent viscera is frequently required, but complete tumor resection (with negative histologic margins) is difficult, owing to the proximity of vital structures.⁵³ Retroperitoneal sarcoma remains an insidious disease, with a generally inexorable course. Most of these tumors will recur, eventually causing death, underscoring the need for better control.⁵⁴⁻⁵⁶

RADIOTHERAPY

The cytotoxic effects⁵⁷ and therapeutic role⁵⁸ of radiotherapy in treating soft-tissue sarcomas are well described. Radiotherapy should be considered for high-grade tumors of the limbs (unless margins are very wide) and for intermediate-grade tumors of the limbs with close or positive histologic margins.⁴⁴ Radiotherapy has little role in primary low-grade soft-tissue sarcoma, although it should be considered for a recurrence.

Radiotherapy is delivered as either external-beam therapy or brachytherapy. The latter involves the insertion of radioactive “seeds” or wires (usually iridium-192) into surgically placed catheters traversing the tumor bed. Brachytherapy has theoretical advantages postoperatively, given the hypoxic nature of the wound and the radiobiologic characteristics of the inverse-square law (local doses are high, but the dose decreases proportionally with increasing distance from the tumor). These advantages are even more important in patients who have already undergone external-beam radiotherapy.⁵⁹ No randomized clinical trial has compared these types of delivery. Not all sites are suitable for brachytherapy, and many units prefer to perform external-beam therapy with its use of standardized fields. Occasionally, both methods are combined — for example, when a large external-beam field is used with a brachytherapy boost to a specific area.

Radiotherapy alone is considered when surgery is inappropriate or declined by the patient; it achieves rates of local control of 30 to 60 percent.⁶⁰ More commonly, operative treatment is coupled with adjuvant radiotherapy on the basis of evidence demonstrating similar survival rates after limb-conserving surgery with radiotherapy and after amputation.^{44,61} Optimal timing remains unclear. A lower total dose of radiotherapy (50 Gy) is required when it is delivered preoperatively. Postoperatively, a total of 60 to 66 Gy is usually delivered to maximize killing of hypoxic tumor cells. One trial of external-beam therapy in patients with soft-tissue sarcoma of the limbs demonstrated similar effectiveness whether therapy was administered preoperatively or postoperatively. Functional outcome in the group treated preoperatively was slightly better but was associated with a doubling in the incidence of wound-healing problems.⁶² Counterintuitively, delaying postoperative radiotherapy does not significantly worsen the rate of late control of local disease.⁶³

Because patients with retroperitoneal soft-tissue sarcoma generally die from a local recurrence, improved local control could have a great effect. Postoperative radiotherapy presents particular challenges at this site; large areas generally require irradiation, and the occurrence of side effects in many organs limits the doses. The preoperative⁶⁴ or intraoperative^{54,56} use of radiotherapy theoretically overcomes these problems, but improvements have been minimal in practice. Enhanced targeting and delivery of radiotherapy with the use of intensity-

modulated techniques represent a potential advance.⁶⁴

CHEMOTHERAPY

Whereas the goal of surgery and radiotherapy is local control of the tumor, the aim of chemotherapy is systemic control, which may be therapeutic, adjuvant, or palliative. Although some subtypes of soft-tissue sarcoma are sensitive to chemotherapeutic agents, the outcome of therapeutic chemotherapy is unsatisfactory overall, and the use of adjuvant chemotherapy is controversial. A meta-analysis of adjuvant chemotherapy did not demonstrate an overall survival advantage, although progression-free survival improved.⁶⁵ One small study of adjuvant chemotherapy reported a small survival benefit (but an identical rate of metastases) in selected patients with high-grade soft-tissue sarcoma of the limbs treated with an intensive regimen.⁶⁶

Small round-cell tumors are treated initially with combination chemotherapy. This approach has dramatically improved overall survival among patients with Ewing's sarcoma, from under 10 percent before the introduction of systemic treatment to greater than 60 percent. The use of local therapy remains important. Radiotherapy alone is inferior to surgery for local control in patients with Ewing's sarcoma. Improved survival is associated with increased rates of surgical intervention.⁶⁷ Cyclophosphamide and ifosfamide, vincristine, doxorubicin, dactinomycin, and etoposide have all been used to treat these tumors.⁶⁸ Prognosis is predicated on the size, site, and stage of the tumor, and the histologic response to induction chemotherapy is the most important prognostic factor on multivariate analysis — histologic examination of tumors resected after induction therapy showed that necrosis of greater than 90 percent of the tumor confers a significantly better outcome than lesser degrees of necrosis, irrespective of tumor size.⁶⁹ Patients with Ewing's sarcoma may benefit from intensive regimens that include ifosfamide. High-dose chemotherapy with salvage of autologous peripheral-blood progenitor cells may be useful and is being compared prospectively with maintenance therapy in a multicenter study in Europe and North America (intensive induction therapy with vincristine, ifosfamide, doxorubicin, and etoposide is followed by high-dose melphalan with busulfan).⁷⁰

The use of traditional generic approaches to chemotherapy belies the heterogeneity of soft-tissue sarcomas. Chemosensitivity varies according to the

tumor subtype, and the likelihood of a response and survival is further influenced by the tumor grade, the patient's age, performance status, and the timing of metastatic disease.⁷¹ Leiomyosarcoma, for example, responds variably to conventional chemotherapy, depending on the site and grade of the tumor. Uterine leiomyosarcoma is particularly aggressive, but it may respond to high-dose gemcitabine with docetaxel.⁷² Facial and scalp angiosarcoma may respond to paclitaxel,⁷³ and taxanes may have broader utility against angiosarcomas at other sites. A pegylated liposomal formulation of doxorubicin (with reduced toxicity)⁷⁴ has also been reported to be active against angiosarcomas.⁷⁵

Chemotherapy is palliative for most patients with unresectable or metastatic disease. Ifosfamide and doxorubicin are routinely used in this setting; doxorubicin as a single agent is considered the drug of choice. Recent studies have reevaluated ifosfamide dosing,⁷⁶ and high-dose ifosfamide with doxorubicin is commonly used for younger patients with aggressive tumors; response rates of approximately 50 to 60 percent have been reported.⁷⁷ It remains unclear whether this approach improves survival, which is on the order of 12 months in this situation.⁷¹

Trabectedin (Yondelis, PharmaMar), a natural product from the marine tunicate *Ecteinascidia turbinata* that selectively inhibits DNA transcription,⁷⁸ is a new agent that has shown some activity in advanced disease refractory to conventional cytotoxic drugs. It appears to induce a low rate of objective remission (4 percent) but a high rate of disease stabilization (a 24 percent rate of progression-free survival at six months), though it is moderately toxic.⁷⁹

TARGETED MOLECULAR THERAPY

Encouraging progress is occurring with the use of therapies directed against specific molecular targets associated with soft-tissue sarcoma. Gastrointestinal stromal tumor, the best-known example, is largely driven by activating mutations in the proto-oncogene *KIT*, a receptor tyrosine kinase, as reported by Hirota et al. in 1998.⁸⁰ Immunohistochemical detection of the resultant protein, KIT, is a reliable means of identifying this tumor.⁸¹ The protein tyrosine kinase inhibitor imatinib is the treatment of choice for advanced inoperable or metastatic gastrointestinal stromal tumor, and its role in the preoperative and adjuvant setting is under evaluation. Trials have defined side-effect profiles,⁸² response rates (more than 60 percent),⁸³ and dose-response

Table 3. Effect of KIT Mutations on the Response to Imatinib in Patients with Gastrointestinal Stromal Tumors.*

Exon	Site	Incidence	Response
		percent	
11	Juxtamembrane domain	67	85
9	External domain	17	45
13	TK1	2	?
17	TK2	2	?
None	—†	13	10

* Data are from Heinrich et al.⁴¹ More than 90 percent of patients with gastrointestinal stromal tumors have activating *KIT* or *PDGFRA* mutations.

† Some tumors may have mutant *PDGFRA*.

relationships. One trial comparing daily doses of 400 mg and 800 mg suggests that the higher dose improves progression-free survival and that patients whose disease progresses during treatment with the lower dose may have a response to the higher dose.⁸⁴

The specific molecular alteration in gastrointestinal stromal tumors is a critical determinant of response. Mutations in exon 11 of *c-KIT* (coding for the intracellular juxtamembrane domain) account for nearly 70 percent of cases and are associated with a rate of response to imatinib of 85 percent (Table 3). However, imatinib is less effective in tumors without *KIT* mutations or other mutations.⁴¹ Activating mutations in the platelet-derived growth factor receptor α (*PDGFRA*) gene may also drive gastrointestinal stromal tumors.⁸⁵ Since *PDGFRA* is also an imatinib substrate, some tumors without *KIT* mutations respond to imatinib, owing to the inhibition of *PDGFRA*. However, unlike *KIT* mutations, most *PDGFRA*-activating mutations occur in the kinase domain, and such mutations are unresponsive to imatinib.⁴¹

Other subtypes of soft-tissue sarcoma with specific molecular targets have been identified. Dermatofibrosarcoma protuberans and the related giant-cell fibrosarcoma are driven by a translocation causing fusion of the collagen I type 1 α (*COL1A1*) and platelet-derived growth factor β (*PDGFB*) genes (Table 2). The resultant fusion protein is processed to functional *PDGFB*.⁸⁶ Since imatinib inhibits the receptor of *PDGFB*, it can be effective in the treatment of dermatofibrosarcoma protuberans⁸⁷; this agent might be useful for patients with locally recurrent inoperable disease or metastatic spread.

Synovial sarcoma is associated with a translocation resulting in fusion of the synovial sarcoma genes *SYT* and *SSX1* or *SSX2*,⁴⁰ with the fusion protein capable of acting as a transcriptional regulator. Synovial sarcomas may express epidermal growth factor receptors,^{88,89} and the epidermal growth factor receptor inhibitor gefitinib is currently being evaluated in a phase 2 trial of patients with synovial sarcoma conducted by the European Organization for Research and Treatment of Cancer (EORTC).

Angiogenesis is a potential therapeutic target. Soft-tissue sarcomas express vascular endothelial growth factor.⁹⁰ The efficacy of a vascular endothelial growth factor–neutralizing antibody (bevacizumab) in other tumors^{91,92} raises the possibility that the angiogenic process could also be inhibited in sarcomas. One current National Cancer Institute trial (03-C-0110) is evaluating bevacizumab in patients with Kaposi's sarcoma, and the EORTC is setting up clinical studies of inhibitors of vascular endothelial growth factor receptor tyrosine kinase in other sarcomas.

FOLLOW-UP

Post-treatment surveillance (by means of clinical examination and chest radiography or CT) is recommended to detect treatable recurrence and metastasis.⁹³ Recurrence rates of 5 to 10 percent might be expected after optimal treatment of soft-tissue sarcomas of the limbs. The utility of CT and MRI for detecting subclinical local recurrence has not been established, but these approaches may be more useful for detecting deep lesions. Since two thirds of recurrences occur within two years,³³ follow-up should be most intense during this period.

Planned post-treatment surveillance enables rapid enlistment of palliative options in patients with incurable disease. However, there is little evidence that early detection of recurrence has a major influence on survival. For every patient whose life is saved by amputation, pulmonary metastasectomy, or aggressive chemotherapy, many others undergo ultimately futile therapies with little benefit — patients need appropriate information from their clinicians in order to choose the best treatment options. Issues related to the quality of life deserve careful consideration.⁹⁴

OPTIONS FOR ADVANCED DISEASE

All three major approaches to treatment — systemic chemotherapy, radiotherapy, and surgery — may prove useful in patients with advanced disease, de-

pending on the circumstances. Systemic chemotherapy has a palliative role, as was discussed earlier. Radiotherapy may provide substantial control of symptoms, particularly for patients with inoperable localized symptomatic disease.

Surgery with a goal of limb salvage is useful for locally recurrent disease. Reconstruction is more frequently needed in this setting. Amputation should be considered in patients with advanced disease, if severe pain, fungation, or bleeding is present. Nodal metastasis occurs in only 1 to 5 percent of patients with soft-tissue sarcoma, most frequently in those with epithelioid sarcoma or rhabdomyosarcoma.⁹⁵ Nodal involvement is classified as stage IV disease, equivalent to distant metastatic disease, although the prognosis for patients with the former is perhaps slightly better.⁹⁶ Therapeutic nodal dissection provides adequate local control in most patients. Pulmonary metastasectomy may benefit certain patients, resulting in medium- to long-term survival for some patients (with few metastases appearing late after primary resection).^{97,98}

Isolated limb perfusion is appropriate for some patients with advanced soft-tissue sarcoma of the limbs. Isolated limb perfusion delivers high regional doses of chemotherapeutic agents through an extracorporeal circuit.⁹⁹ Melphalan is most commonly used, and the addition of tumor necrosis factor α (licensed in Europe but not in the United States)

may further improve results: limb salvage is reported to be possible in 80 percent of selected patients who receive perfusion who would otherwise have required amputation or functionally debilitating treatment.⁹⁹ Tumor necrosis factor α targets the tumor neovasculature, causing vasodilatation and increasing vascular permeability (increasing the penetration of melphalan into the tumor), followed by prompt shutdown of measurable metabolic activity in the tumor.¹⁰⁰

CONCLUSIONS

Surgery is the mainstay of treatment for soft-tissue sarcomas; radiotherapy is useful in selected cases. Conventional chemotherapy has little effect on the outcome of most tumors, but the availability of novel targeted agents may drastically improve the prognosis of some soft-tissue sarcomas, as has been demonstrated with imatinib in the case of gastrointestinal stromal tumors. Prompt diagnosis and referral are desirable, since the size of the tumor at presentation is a continuous variable for the risk of local recurrence and metastatic disease.

Dr. Judson reports having received consulting fees from Pharmar, which manufactures trabectedin, and lecture fees from Novartis, which manufactures imatinib.

We are indebted to Drs. Eleanor Moskovic and Frank Saran from the Royal Marsden Hospital Sarcoma Unit for advice on imaging and radiotherapy, respectively.

REFERENCES

- Wietz J, Antonescu CR, Brennan ME. Localized extremity soft tissue sarcoma: improved knowledge with unchanged survival over time. *J Clin Oncol* 2003;21:2719-25.
- Mankin HJ, Mankin CJ, Simon MA. The hazards of the biopsy, revisited. *J Bone Joint Surg Am* 1996;78:656-63.
- Ray-Coquard I, Thiesse P, Ranchère-Vince D, et al. Conformity to clinical practice guidelines, multidisciplinary management and outcomes of treatment for soft tissue sarcomas. *Ann Oncol* 2004;15:307-15.
- Rydholm A. Centralization of soft tissue sarcoma: the southern Sweden experience. *Acta Orthop Scand Suppl* 1997;273:4-8.
- Van Dalen T, Hennipman A, Van Coevorden F, et al. Evaluation of a clinically applicable post-surgical classification system for primary retroperitoneal soft-tissue sarcoma. *Ann Surg Oncol* 2004;11:483-90.
- Clasby R, Tilling K, Smith MA, Fletcher CD. Variable management of soft tissue sarcoma: regional audit with implications for specialist care. *Br J Surg* 1997;84:1692-6.
- Jemal A, Tiwari RC, Murray T, et al. Cancer statistics, 2004. *CA Cancer J Clin* 2004;54:8-29.
- Arndt CAS, Crist WM. Common musculoskeletal tumors of childhood and adolescence. *N Engl J Med* 1999;341:342-52.
- Zahm SH, Fraumeni JF Jr. The epidemiology of soft tissue sarcoma. *Semin Oncol* 1997;24:504-14.
- Levi F, La Vecchia C, Randimbison L, Te VC. Descriptive epidemiology of soft tissue sarcomas in Vaud, Switzerland. *Eur J Cancer* 1999;35:1711-6.
- McClain KL, Leach CT, Jenson HB, et al. Association of Epstein-Barr virus with leiomyosarcomas in young people with AIDS. *N Engl J Med* 1995;332:12-8.
- Brady MS, Gaynor JJ, Brennan ME. Radiation-associated sarcoma of bone and soft tissue. *Arch Surg* 1992;127:1379-85.
- Wong FL, Boice JD Jr, Abramson DH, et al. Cancer incidence after retinoblastoma: radiation dose and sarcoma risk. *JAMA* 1997;278:1262-7.
- Strong LC, Williams WR, Tainsky MA. The Li-Fraumeni syndrome: from clinical epidemiology to molecular genetics. *Am J Epidemiol* 1992;135:190-9.
- Rydholm A. Improving the management of soft tissue sarcoma: diagnosis and treatment should be given in specialist centres. *BMJ* 1998;317:93-4.
- Demas BE, Heelan RT, Lane J, Marcove R, Hajdu S, Brennan ME. Soft-tissue sarcomas of the extremities: comparison of MR and CT in determining the extent of disease. *AJR Am J Roentgenol* 1988;150:615-20.
- Sanders TG, Parsons TW III. Radiographic imaging of musculoskeletal neoplasia. *Cancer Control* 2001;8:221-31.
- Bastiaannet E, Groen H, Jager PL, et al. The value of FDG-PET in the detection, grading and response to therapy of soft tissue and bone sarcomas: a systematic review and meta-analysis. *Cancer Treat Rev* 2004;30:83-101.
- Bar-Shalom R, Yefremov N, Guralnik L, et al. Clinical performance of PET/CT in evaluation of cancer: additional value for diagnostic imaging and patient management. *J Nucl Med* 2003;44:1200-9.
- Somer EJ, Marsden PK, Benatar NA, Goodey J, O'Doherty MJ, Smith MA. PET-MR image fusion in soft tissue sarcoma: accuracy, reliability and practicality of interactive point-based and automated mutual information techniques. *Eur J Nucl Med Mol Imaging* 2003;30:54-62.
- Vaidya SJ, Payne GS, Leach MO, Pinkerton CR. Potential role of magnetic reso-

- nance spectroscopy in assessment of tumour response in childhood cancer. *Eur J Cancer* 2003;39:728-35.
22. Hoerber I, Spillane AJ, Fisher C, Thomas JM. Accuracy of biopsy techniques for limb and limb girdle soft tissue tumors. *Ann Surg Oncol* 2001;8:80-7.
23. Heslin MJ, Lewis JJ, Woodruff JM, Brennan MF. Core needle biopsy for diagnosis of extremity soft tissue sarcoma. *Ann Surg Oncol* 1997;4:425-31.
24. Trovik CS, Bauer HC, Brosjo O, Skoog L, Soderlund V. Fine needle aspiration (FNA) cytology in the diagnosis of recurrent soft tissue sarcoma. *Cytopathology* 1998;9:320-8.
25. Alvegard TA, Berg NO. Histopathology peer review of high-grade soft tissue sarcoma: the Scandinavian Sarcoma Group experience. *J Clin Oncol* 1989;7:1845-51.
26. Clark MA, Thomas JM. Ports site recurrence after laparoscopy for staging of retroperitoneal sarcoma. *Surg Laparosc Endosc Percutan Tech* 2003;13:290-1.
27. Burkill GJC, Badran M, Al-Muderis O, et al. Malignant gastrointestinal stromal tumor: distribution, imaging features, and pattern of metastatic spread. *Radiology* 2003;226:527-32.
28. Fletcher CDM, Unni KK, Mertens F, eds. Pathology and genetics of tumours of soft tissue and bone. Vol. 5 of World Health Organization classification of tumours. Lyon, France: IARC Press, 2002.
29. Guillou L, Coindre JM, Bonichon F, et al. Comparative study of the National Cancer Institute and French Federation of Cancer Centers Sarcoma Group grading systems in a population of 410 adult patients with soft tissue sarcoma. *J Clin Oncol* 1997;15:350-62.
30. Greene FL, Page DL, Fleming ID, et al, eds. *AJCC cancer staging manual*. 6th ed. New York: Springer-Verlag, 2002.
31. Ramanathan RC, A'Hern R, Fisher C, Thomas JM. Modified staging system for extremity soft tissue sarcomas. *Ann Surg Oncol* 1999;6:57-69.
32. Pisters PW, Leung DH, Woodruff J, Shi W, Brennan MF. Analysis of prognostic factors in 1,041 patients with localized soft tissue sarcomas of the extremities. *J Clin Oncol* 1996;14:1679-89.
33. Stojadinovic A, Leung DH, Allen P, Lewis JJ, Jaques DP, Brennan MF. Primary adult soft tissue sarcoma: time-dependent influence of prognostic variables. *J Clin Oncol* 2002;20:4344-52.
34. Kattan MW, Leung DH, Brennan MF. Postoperative nomogram for 12-year sarcoma-specific death. *J Clin Oncol* 2002;20:791-6.
35. Fletcher CD, Berman JJ, Corless C, et al. Diagnosis of gastrointestinal stromal tumors: a consensus approach. *Hum Pathol* 2002;33:459-65.
36. Segal NH, Pavlidis NA, Antonescu CR, et al. Classification and subtype prediction of adult soft tissue sarcoma by functional genomics. *Am J Pathol* 2003;163:691-700.
37. Stratton MR, Moss S, Warren W, et al. Mutation of the p53 gene in human soft tissue sarcomas: association with abnormalities of the RB1 gene. *Oncogene* 1990;5:1297-301.
38. Kruzlock RP, Hansen ME. Molecular genetics and cytogenetics of sarcomas. *Hematol Oncol Clin North Am* 1995;9:513-40.
39. Karpeh MS, Brennan MF, Cance WG, et al. Altered patterns of retinoblastoma gene product expression in adult soft-tissue sarcomas. *Br J Cancer* 1995;72:986-91.
40. Ladanyi M, Antonescu CR, Leung DH, et al. Impact of SYT-SSX fusion type on the clinical behavior of synovial sarcoma: a multi-institutional retrospective study of 243 patients. *Cancer Res* 2002;62:135-40.
41. Heinrich MC, Corless CL, Demetri GD, et al. Kinase mutations and imatinib response in patients with metastatic gastrointestinal stromal tumor. *J Clin Oncol* 2003;21:4342-9.
42. Lee YF, John M, Edwards S, et al. Molecular classification of synovial sarcomas, leiomyosarcomas and malignant fibrous histiocytomas by gene expression profiling. *Br J Cancer* 2003;88:510-5.
43. Nielsen TO, West RB, Linn SC, et al. Molecular characterisation of soft tissue tumours: a gene expression study. *Lancet* 2002;359:1301-7.
44. McCarter MD, Jaques DP, Brennan MF. Randomized clinical trials in soft tissue sarcoma. *Surg Oncol Clin N Am* 2002;11:11-22.
45. Bowden L, Booher RJ. The principles and technique of resection of soft parts for sarcoma. *Surgery* 1958;44:963-76.
46. Gerrand CH, Wunder JS, Kandel RA, et al. Classification of positive margins after resection of soft-tissue sarcoma of the limb predicts the risk of local recurrence. *J Bone Joint Surg Br* 2001;83:1149-55.
47. Schwartz DL, Einck J, Bellon J, Laramore GE. Fast neutron radiotherapy for soft tissue and cartilaginous sarcomas at high risk for local recurrence. *Int J Radiat Oncol Biol Phys* 2001;50:449-56.
48. Bickels J, Wittig JC, Kollender Y, Kellar-Graney KL, Malawer MM, Meller I. Sciatic nerve resection: is that truly an indication for amputation? *Clin Orthop* 2002;399:201-4.
49. Pitcher ME, Thomas JM. Functional compartmental resection for soft tissue sarcomas. *Eur J Surg Oncol* 1994;20:441-5.
50. Clark MA, Thomas JM. Amputation for soft-tissue sarcoma. *Lancet Oncol* 2003;4:335-42.
51. Merimsky O, Kollender Y, Inbar M. Is forequarter amputation justified for palliation of intractable cancer symptoms? *Oncology* 2001;60:55-9.
52. Langstein HN, Robb GL. Reconstructive approaches in soft tissue sarcoma. *Semin Surg Oncol* 1999;17:52-65.
53. Singer S, Antonescu CR, Riedel E, Brennan MF. Histologic subtype and margin of resection predict pattern of recurrence and survival for retroperitoneal liposarcoma. *Ann Surg* 2003;238:358-71.
54. Alektiar KM, Hu K, Anderson L, Brennan MF, Harrison LB. High-dose-rate intraoperative radiation therapy (HDR-IORT) for retroperitoneal sarcomas. *Int J Radiat Oncol Biol Phys* 2000;47:157-63.
55. Rossi CR, Deraco M, De Simone M, et al. Hyperthermic intraperitoneal intraoperative chemotherapy after cytoreductive surgery for the treatment of abdominal sarcomatosis: clinical outcome and prognostic factors in 60 consecutive patients. *Cancer* 2004;100:1943-50.
56. Sindelar HE, Kinsella TJ, Chen PW, et al. Intraoperative radiotherapy in retroperitoneal sarcomas: final results of a prospective, randomized clinical trial. *Arch Surg* 1993;128:402-10.
57. Lichter AS, Lawrence TS. Recent advances in radiation oncology. *N Engl J Med* 1995;332:371-9.
58. Strander H, Turesson I, Cavallin-Stahl E. A systematic overview of radiation therapy effects in soft tissue sarcomas. *Acta Oncol* 2003;42:516-31.
59. Janjan N, Crane C, Delclos M, Ballo M. Brachytherapy for locally recurrent soft-tissue sarcoma. *Am J Clin Oncol* 2002;25:9-15.
60. Tepper JE, Suit HD. Radiation therapy alone for sarcoma of soft tissue. *Cancer* 1985;56:475-9.
61. Rosenberg SA, Tepper J, Glatstein E, et al. The treatment of soft-tissue sarcomas of the extremities: prospective randomized evaluations of (1) limb-sparing surgery plus radiation therapy compared with amputation and (2) the role of adjuvant chemotherapy. *Ann Surg* 1982;196:305-15.
62. O'Sullivan B, Davis AM, Turcotte R, et al. Preoperative versus postoperative radiotherapy in soft-tissue sarcoma of the limbs: a randomised trial. *Lancet* 2002;359:2235-41.
63. Ballo MT, Zagars GK, Cormier JN, et al. Interval between surgery and radiotherapy: effect on local control of soft tissue sarcoma. *Int J Radiat Oncol Biol Phys* 2004;58:1461-7.
64. O'Sullivan B, Ward I, Catton C. Recent advances in radiotherapy for soft-tissue sarcoma. *Curr Oncol Rep* 2003;5:274-81.
65. Sarcoma Meta-analysis Collaboration. Adjuvant chemotherapy for localised resectable soft-tissue sarcoma of adults: meta-analysis of individual data. *Lancet* 1997;350:1647-54.
66. Frustaci S, Gherlinzoni F, De Paoli A, et al. Adjuvant chemotherapy for adult soft tissue sarcomas of the extremities and girdles: results of the Italian randomized cooperative trial. *J Clin Oncol* 2001;19:1238-47.
67. Schuck A, Ahrens S, Paulussen M, et al. Local therapy in localized Ewing tumors: results of 1058 patients treated in the CESS 81, CESS 86, and EICESS 92 trials. *Int J Radiat Oncol Biol Phys* 2003;55:168-77.
68. Kolb EA, Kushner BH, Gorlick R, et al. Long-term event-free survival after intensive

- chemotherapy for Ewing's family of tumors in children and young adults. *J Clin Oncol* 2003;21:3423-30.
69. Oberlin O, Deley MC, Bui BN, et al. Prognostic factors in localized Ewing's tumours and peripheral neuroectodermal tumours: the third study of the French Society of Paediatric Oncology (EW88 study). *Br J Cancer* 2001;85:1646-54.
70. Strauss SJ, McTiernan A, Driver D, et al. Single center experience of a new intensive induction therapy for Ewing's family of tumors: feasibility, toxicity, and stem cell mobilization properties. *J Clin Oncol* 2003;21:2974-81.
71. Van Glabbeke M, van Oosterom AT, Oosterhuis JW, et al. Prognostic factors for the outcome of chemotherapy in advanced soft tissue sarcoma: an analysis of 2,185 patients treated with anthracycline-containing first-line regimens — a European Organization for Research and Treatment of Cancer Soft Tissue and Bone Sarcoma Group Study. *J Clin Oncol* 1999;17:150-7.
72. Hensley ML, Maki R, Venkatraman E, et al. Gemcitabine and docetaxel in patients with unresectable leiomyosarcoma: results of a phase II trial. *J Clin Oncol* 2002;20:2824-31.
73. Fata R, O'Reilly E, Ilson D, et al. Paclitaxel in the treatment of patients with angiosarcoma of the scalp or face. *Cancer* 1999;86:2034-7.
74. Judson I, Radford JA, Harris M, et al. Randomised phase II trial of pegylated liposomal doxorubicin (DOXIL/CAELYX) versus doxorubicin in the treatment of advanced or metastatic soft tissue sarcoma: a study by the EORTC Soft Tissue and Bone Sarcoma Group. *Eur J Cancer* 2001;37:870-7.
75. Eiling S, Lischner S, Busch JO, Rothaupt D, Christophers E, Hauschild A. Complete remission of a radio-resistant cutaneous angiosarcoma of the scalp by systemic treatment with liposomal doxorubicin. *Br J Dermatol* 2002;147:150-3.
76. van Oosterom AT, Mouridsen HT, Nielsen OS, et al. Results of randomised studies of the EORTC Soft Tissue and Bone Sarcoma Group (STBSG) with two different ifosfamide regimens in first- and second-line chemotherapy in advanced soft tissue sarcoma patients. *Eur J Cancer* 2002;38:2397-406.
77. Patel SR, Vadhan-Raj S, Burgess MA, et al. Results of two consecutive trials of dose-intensive chemotherapy with doxorubicin and ifosfamide in patients with sarcomas. *Am J Clin Oncol* 1998;21:317-21.
78. D'Incalci M, Jimeno J. Preclinical and clinical results with the natural marine product ET-743. *Expert Opin Investig Drugs* 2003;12:1843-53.
79. Yovine A, Riofrio M, Blay JY, et al. Phase II study of ecteinascidin-743 in advanced pretreated soft tissue sarcoma patients. *J Clin Oncol* 2004;22:890-9.
80. Hirota S, Isozaki K, Moriyama Y, et al. Gain-of-function mutations of c-kit in human gastrointestinal stromal tumors. *Science* 1998;279:577-80.
81. Kindblom LG, Remotti HE, Aldenborg F, Meis-Kindblom JM. Gastrointestinal pacemaker cell tumor (GIPACT): gastrointestinal stromal tumors show phenotypic characteristics of the interstitial cells of Cajal. *Am J Pathol* 1998;152:1259-69.
82. van Oosterom AT, Judson I, Verweij J, et al. Safety and efficacy of imatinib (STI571) in metastatic gastrointestinal stromal tumours: a phase I study. *Lancet* 2001;358:1421-3.
83. Demetri GD, von Mehren M, Blanke CD, et al. Efficacy and safety of imatinib mesylate in advanced gastrointestinal stromal tumors. *N Engl J Med* 2002;347:472-80.
84. Verweij J, Casali PG, Zalberg J, et al. Early efficacy comparison of two doses of imatinib for the treatment of advanced gastrointestinal stromal tumors (GIST): interim results of a randomised phase III trial from the EORTC-STBSG, ISG, and AGITG. *Proc Am Soc Clin Oncol* 2003;22:814. abstract.
85. Heinrich MC, Corless CL, Duensing A, et al. PDGFRA activating mutations in gastrointestinal stromal tumors. *Science* 2003;299:708-10.
86. Shimizu A, O'Brien KP, Sjoblom T, et al. The dermatofibrosarcoma protuberans-associated collagen type I alpha1/platelet-derived growth factor (PDGF) B-chain fusion gene generates a transforming protein that is processed to functional PDGF-B. *Cancer Res* 1999;59:3719-23.
87. Maki RG, Awan RA, Dixon RH, Jhanwar S, Antonescu CR. Differential sensitivity to imatinib of 2 patients with metastatic sarcoma arising from dermatofibrosarcoma protuberans. *Int J Cancer* 2002;100:623-6.
88. Gusterson B, Cowley G, McIlhinney J, Ozanne B, Fisher C, Reeves B. Evidence for increased epidermal growth factor receptors in human sarcomas. *Int J Cancer* 1985;36:689-93.
89. Nielsen TO, Hsu FO, O'Connell JX, et al. Tissue microarray validation of epidermal growth factor receptor and SALL2 in synovial sarcoma with comparison to tumors of similar histology. *Am J Pathol* 2003;163:1449-56.
90. Hayes AJ, Mostyn-Jones A, Koban MU, A'Hern R, Burton P, Thomas JM. Serum vascular endothelial growth factor as a tumour marker in soft tissue sarcoma. *Br J Surg* 2004;91:242-7.
91. Yang JC, Haworth L, Sherry RM, et al. A randomized trial of bevacizumab, an anti-vascular endothelial growth factor antibody, for metastatic renal cancer. *N Engl J Med* 2003;349:427-34.
92. Hurwitz H, Fehrenbacher L, Novotny W, et al. Bevacizumab plus irinotecan, fluorouracil, and leucovorin for metastatic colorectal cancer. *N Engl J Med* 2004;350:2335-42.
93. Whooley BP, Gibbs JF, Mooney MM, McGrath BE, Kraybill WG. Primary extremity sarcoma: what is the appropriate follow-up? *Ann Surg Oncol* 2000;7:9-14.
94. Merimsky O, Kollender Y, Inbar M, Chaitchick S, Meller I. Palliative major amputation and quality of life in cancer patients. *Acta Oncol* 1997;36:151-7.
95. Fong Y, Coit DG, Woodruff JM, Brennan MF. Lymph node metastasis from soft tissue sarcoma in adults: analysis of data from a prospective database of 1772 sarcoma patients. *Ann Surg* 1993;217:72-7.
96. Behranwala KA, A'Hern R, Omar AM, Thomas JM. Prognosis of lymph node metastasis in soft tissue sarcoma. *Ann Surg Oncol* 2004;11:714-9.
97. Billingsley KG, Burt ME, Jara E, et al. Pulmonary metastases from soft tissue sarcoma: analysis of patterns of diseases and postmetastasis survival. *Ann Surg* 1999;229:602-12.
98. Temple LKF, Brennan MF. The role of pulmonary metastasectomy in soft tissue sarcoma. *Semin Thorac Cardiovasc Surg* 2002;14:35-44.
99. Eggermont AMM, de Wilt JHW, ten Hagen TLM. Current uses of isolated limb perfusion in the clinic and a model system for new strategies. *Lancet Oncol* 2003;4:429-37.
100. Sijens PE, Eggermont AM, van Dijk PV, Oudkerk M. 31P magnetic resonance spectroscopy as predictor of clinical response in human extremity sarcomas treated by single dose TNF-alpha + melphalan isolated limb perfusion. *NMR Biomed* 1995;8:215-24.

Copyright © 2005 Massachusetts Medical Society.