

CHEST[®]

THE CARDIOPULMONARY
AND CRITICAL CARE JOURNAL

FOR PULMONOLOGISTS, CARDIOLOGISTS, CARDIOTHORACIC SURGEONS,
CRITICAL CARE PHYSICIANS, AND RELATED SPECIALISTS

Tracheomalacia and Tracheobronchomalacia in Children and Adults: An In-depth Review

Kelly A. Carden, Philip M. Boiselle, David A. Waltz and Armin Ernst
Chest 2005;127;984-1005
DOI: 10.1378/chest.127.3.984

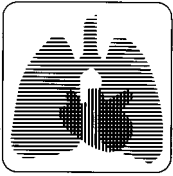
This information is current as of July 26, 2005

The online version of this article, along with updated information and services, is
located on the World Wide Web at:

<http://www.chestjournal.org/cgi/content/full/127/3/984>

CHEST is the official journal of the American College of Chest Physicians. It has been published monthly since 1935. Copyright 2005 by the American College of Chest Physicians, 3300 Dundee Road, Northbrook IL 60062. All rights reserved. No part of this article or PDF may be reproduced or distributed without the prior written permission of the copyright holder. ISSN: 0012-3692.

A M E R I C A N C O L L E G E O F
 C H E S T
P H Y S I C I A N S



reviews

Tracheomalacia and Tracheobronchomalacia in Children and Adults*

An In-depth Review

Kelly A. Carden, MD; Philip M. Boiselle, MD, FCCP; David A. Waltz, MD; and Armin Ernst, MD, FCCP

Tracheomalacia and tracheobronchomalacia are disorders that are encountered in both pediatric and adult medicine. Despite increasing recognition of these disease processes, there remains some uncertainty regarding their identification, causes, and treatment. This article is intended to be a comprehensive review of both the adult and pediatric forms of the diseases, and includes sections on the historical aspects of the disorders, and their classification, associated conditions, histopathology, and natural history. We also review the various modalities that are used for diagnosis as well as the state of the art of treatment, including airway stent placement and surgical intervention. (CHEST 2005; 127:984–1005)

Key words: bronchomalacia; esophageal atresia; tracheobronchomalacia; tracheoesophageal fistula; tracheomalacia

Abbreviations: CPAP = continuous positive airway pressure; EA = esophageal atresia; FEF = forced expiratory flow; MAC = major airway collapse; TBM = tracheobronchomalacia; TEF = tracheoesophageal fistula; TM = tracheomalacia

Malacia refers to “softness” and, in medical terminology, generally refers to cartilage or bone.¹ Tracheomalacia (TM) refers to a weakness of the trachea, frequently due to reduction and/or atrophy of the longitudinal elastic fibers of the pars membranacea, or impaired cartilage integrity, such that the airway is softer and more susceptible to collapse. By virtue of its compliance, the normal intrathoracic trachea dilates somewhat with inspiration and narrows with expiration, as a reflection of the difference between intrathoracic and intraluminal pressures.^{2–4} In TM, there is accentuation of this physiologic

process, such that exaggerated changes in tracheal diameter occur.⁵ The majority of cases of TM are intrathoracic in nature¹ such that excessive narrowing is most prominent when intrathoracic pressure is substantially greater than intraluminal pressure, as it is during forced expiration, cough, or the Valsalva maneuver.^{6,7} Various degrees of tracheal collapse, and therefore airway obstruction, can result from this narrowing.^{4,8} Less commonly, extrathoracic or cervical TM is seen. In these cases, negative intrapleural pressures are transmitted to the extrathoracic trachea due to pleural reflections such that the upper airway collapses during inspiration.¹ TM may be localized to one portion of the trachea or may involve the entire trachea. If the mainstem bronchi are involved as well, the term *tracheobronchomalacia* (TBM) is employed. It should be noted that, historically, many authors have used TM and TBM interchangeably, especially in studies found in the pediatric literature. Thus, we have paralleled this practice where necessary. The term *bronchomalacia* is used to describe the isolated weakness and easy collapsibility of one or both of the mainstem bronchi

*From the Divisions of Pulmonary and Critical Care Medicine (Drs. Carden and Ernst) Thoracic Imaging (Dr. Boiselle), Beth Israel Deaconess Medical Center; and the Division of Respiratory Diseases (Dr. Waltz), Children’s Hospital, Boston, MA. Manuscript received March 4, 2004; revision accepted September 22, 2004.

Reproduction of this article is prohibited without written permission from the American College of Chest Physicians (e-mail: permissions@chestnet.org).

Correspondence to: Armin Ernst, MD, FCCP, Director, Interventional Pulmonology, Beth Israel Deaconess Medical Center, 330 Brookline Ave, Boston, MA 02446; e-mail: aernst@bidmc.harvard.edu

without tracheal involvement. It is much less common than TM and TBM, and is therefore mentioned only briefly in this review.

Both TM and TBM are becoming more frequently recognized and treated in children and adults, a pattern that may be related to better diagnostic imaging and increased awareness of the condition among clinicians. Despite this, it is still thought to be a relatively underdiagnosed condition, and there remains confusion as to the appropriate treatment. For this article, an exhaustive review of the literature from the late 1800s to the present was undertaken using multiple medical literature search engines and the resources of Harvard Medical School, and the search included references in multiple languages. We herein review the history of pediatric and adult TM and TBM, the classification of these disease processes, the most common signs and symptoms, and the current methods for their diagnosis and treatment.

PEDIATRIC TM AND TBM

History

The earliest references to the disease we now call TM are from the 1930s and 1940s, when clinicians described congenital thoracic vascular abnormalities that resulted in tracheal obstruction.^{9–11} In 1948, Gross and Neuhauser¹² described an infant with cough, wheezing, cyanosis, and spontaneous hyperextension of the head. Her trachea was compressed by an anomalous innominate artery that, despite surgical correction, had structurally deformed the trachea. One year later, Evans¹³ described several infants with symptomatic tracheal narrowing and advocated radiography as the method of choice for diagnosis. In 1950, Kirklin and Claggett¹⁴ suggested that prolonged pressure from anomalous vasculature can lead to the softening of tracheal rings.

In 1952, Holinger et al¹⁵ described the classic clinical features of malacic collapse of the airway lumen on expiration in three infants with dyspnea, stridor, and marked cyanosis. They noted that the symptoms disappeared with the passage of a bronchoscope through the flaccid walls of the trachea. They later suggested¹⁶ that surgery should be performed early in cases of vascular anomalies to “take full, effective advantage of the early growth potential of the constricted trachea.” In 1963, Baxter and Dunbar¹⁷ defined TM as a condition in which the tracheal wall weakens from a softening of the supporting cartilage and by hypotonia of the supporting myoelastic fibers, resulting in easy collapsibility. In addition, they divided the disease into primary and secondary forms. In 1968, Gupta et al¹⁸ reported the

first case of congenital isolated bronchomalacia in a 3-year-old child with a normal trachea but in whom the left mainstem bronchus collapsed to such a degree that the child required pneumonectomy for treatment.

Classification

In children, TM and TBM have been classified in various ways, including by macroscopic appearance, into “generalized” and “localized” disease.¹⁹ However, we adhere to the more commonly used division into congenital disease (also called *primary*) and acquired disease (also called *secondary*).

Congenital or Primary Forms

TM is the most common congenital anomaly of the trachea.²⁰ It can be an isolated finding in healthy infants, but it is more commonly seen in premature infants.²¹ It is believed to be a consequence of the inadequate maturity of tracheobronchial cartilage, either from premature delivery or from an innate immaturity despite normal gestation. Some authors have reported¹⁷ no gender predominance in the primary form of the disease, whereas others have reported^{8,22–24} a definite male predominance.

Disease processes that result in the formation of an abnormal cartilaginous matrix of the trachea are included as primary forms of TM. These associated diseases, which include polychondritis²⁵ and chondromalacia,²⁶ result in dysmaturity of the collagen fibers and weakness in the tracheobronchial tissue. In addition, TM is clearly associated with the mucopolysaccharidoses, such as Hunter syndrome and Hurler syndrome,^{8,27,28} as well as with many other genetic syndromes (Table 1).

The most common associated disease is tracheoesophageal fistula (TEF), which some authors^{29,30} have classified as an acquired form rather than a congenital form of the disease. We and others³¹ think that TEF is more appropriately included as a primary form of the disease because the weakness of the trachea is not caused by compression from other structures but, instead, is due to an inherent weakness of the involved segment of the trachea. Some think that the congenital form of TM is due to a faulty division of the foregut into the trachea and esophagus during embryonic development, with the trachea receiving too much tissue during embryologic separation.^{8,23} This explanation accounts for the pathologic finding of a widened posterior membranous wall as well as the association with TEF and with esophageal atresia (EA). In 75% of pathologic specimens from infants born with TEF and EA, the circumference of the tracheal cartilage is reduced and the membranous trachea is widened, resulting in

Table 1—Diseases Associated With TBM*

Disease	Description
Primary (congenital)	
	Normal infants (idiopathic or primary TM proper)
	Prematurity
	Pulsatile collapse with normal innominate artery
	Congenital abnormalities of the cartilage
	Dyschondroplasia/chondromalacia/chondrodysplasia
	Polychondritis
	Ehlers-Danlos syndrome
	Congenital syndromes associated with TM/TBM
	Mucopolysaccharidosis
	Hurler syndrome
	Hunter syndrome
	CHARGE syndrome
	VATER anomaly
	Trisomy 9
	Trisomy 21
	Atelosteogenesis type 1
	Antley-Bixler syndrome
	11p13 deletion
	22q11 deletion
	18-22 translocation
	Hallermann-Streiff syndrome
	Pfeiffer syndrome
	Blackfan-Diamond syndrome
	Williams-Campbell syndrome
	Kniest dysplasia
	DiGeorge syndrome
	Deletion of 12 q
	Larsen syndrome and Larsen-like syndromes
	Brachmann-de Lange syndrome
	Camptomelic dysplasia
	Pierre-Robin syndrome
	Congenital anomalies associated with TM/TBM
	Tracheoesophageal fistula
	EA with or without laryngeal cleft
	Bronchopulmonary dysplasia
Secondary (acquired)	
	Prolonged intubation
	Tracheotomy
	Severe tracheobronchitis
	Resulting from compression
	Vascular
	Double aortic arch
	Abnormal take-off of the innominate artery
	Anomaly of left pulmonary artery
	Right aortic arch
	Aberrant right subclavian
	Enlarged pulmonary veins
	Cardiac
	Left atrial hypertrophy
	Enlarged left atrium
	Skeletal
	Scoliosis
	Pectus excavatum
	Tumors and cysts
	Teratomas
	Cystic hygromas
	Hemangiomas
	Bronchogenic cysts
	Enterogenic cysts
	Thymoma
	Thymus enlargement
	Goiter
	Lymphatic malformation
	Lymphoma
	Neuroblastoma
	Infection
	Abscess
	Posttraumatic

*CHARGE = colobomata of the eyes, heart defects, choanal atresia, retardation of growth, genital hypoplasia, and ear abnormalities; VATER = vertebral defect, anal atresia, tracheoesophageal fistula, esophageal fistula, and radial/renal dysplasia.

easy collapsibility.³² Blair and colleagues²³ also have reported the presence of esophageal muscle in the posterior wall of the trachea in infants with TEF, EA, or both. On the basis of these findings, it has been proposed that idiopathic primary TM may actually be the result of a faulty foregut division that was not severe enough to cause TEF or EA but did result in an inherent weakness of the trachea.²³

Mustard et al,³³ Moes et al,³⁴ and Cohen³⁵ independently recognized that, although the innominate artery was often implicated in cases of secondary TM, angiographic and surgical data suggested normal positioning of the artery in many cases. We and others²⁹ think that TM in this situation occurs from an inherent tracheal weakness that manifests as a pulsatile movement of an abnormally pliable trachea in the area juxtaposed to a normally placed artery. This condition has been labeled the “pulsatile” form of TM by some authors and should be considered a primary form of the disease.³¹

In the majority of healthy and even premature infants, primary TM is a self-limiting disease. Most infants outgrow the condition by the age of 2 years.^{17,21,36} In the patients with connective tissue disorders and congenital syndromes, the effects of TM often persist and may even be fatal.^{26,37}

Acquired or Secondary Forms

Acquired or secondary TM is caused by the degeneration of normal cartilaginous support from a variety of causes.¹⁷ Acquired TM is more common than the congenital form. There is a male predominance of the acquired form, but the reason for that is unknown.^{16,22} It commonly results from protracted endotracheal intubation,³⁸ with the associated insults of increased airway pressure, oxygen toxicity, and recurrent infections. Premature infants with respiratory distress syndrome seem to be the most predisposed to this condition,^{21,39} as their supporting structures are not yet mature. As more and more premature infants are treated for respiratory distress syndrome, the incidence of TM may very well increase.

Tracheotomy also predisposes the patient to the development of TM.⁴⁰ Not only is the stoma vulnerable, but the cuff site and the impingement point at the distal end of the tube may also be involved.⁴ The mechanisms of action could be pressure necrosis, impairment of the blood supply, infection, or mucosal damage caused by friction.⁴¹ In addition, TM is associated with recurrent tracheobronchitis.^{4,42}

A smaller percentage of secondary TM cases is caused by external tracheal compression from various structures (Table 1). Compression affects the integrity of the tracheal wall and increases the

compliance over that in the adjacent tracheal tissue.⁴ Although some lesions are severe enough to cause persistent obstruction of the airway, many cause only transient collapse with an increase in intrathoracic pressure. The structures implicated in the development of secondary TM through compression include cardiovascular abnormalities, such as double aortic arch,^{8,43-47} abnormal branch of the innominate artery,^{8,16,24,48,49} other vascular rings,⁵⁰ anomalous left pulmonary artery,^{16,51,52} right aortic arch with left ligamentum arteriosum,⁴⁴ and left atrial hypertrophy.⁵³ Skeletal disorders, such as scoliosis⁵⁴ and pectus excavatum,⁵⁵ may cause secondary TM. Last, space-occupying lesions, such as goiters,^{21,56,57} tumors,^{23,29,58} abscesses,²⁹ and cysts,^{8,29,59,60} may compress the trachea. Even after surgical correction of the compressive structure, tracheal weakness and collapse may persist, occasionally requiring additional evaluation and treatment.^{29,61}

Associated Conditions

There are many conditions that are associated with TM. Cardiovascular abnormalities are found in 20 to 58% of patients with TM.^{8,23} These abnormalities include patent ductus arteriosus,⁸ atrial or ventricular septal defects,^{8,23} abnormalities of the aortic arch,^{62,63} hypoplastic left heart, hypoplastic right heart,⁶⁴ Tetralogy of Fallot,⁸ dextrocardia,²³ and valvular stenosis.^{8,23,64} Up to 52% of infants with TM have associated bronchopulmonary dysplasia.^{21,39,65-70} About half of infants with TM have gastroesophageal reflux disease.^{21,71,72} Reflux has been seen in up to 78% of patients with life-threatening TM and may require fundoplication,²³ either simultaneously with TM surgical correction^{73,74} or sequentially to it.^{75,76} In addition, subglottic stenosis,²¹ laryngomalacia,^{1,21,77} and vocal cord paralysis^{8,21} may be seen. TM can occur in the setting of an immature autonomic nervous system.^{8,78} Neurologic impairment is seen in 8 to 48% of infants with TM.^{8,21,79} Mair and Parsons⁸ have also reported severe developmental delay in 26% of infants with TM.

Histopathologic Characteristics

The pioneers in the histology of the trachea in TM are Wailoo and Emery,⁸⁰ who in 1980 compiled data from 1,000 sequential autopsies of children of all ages. Of the 74 children who had no known congenital disease but did have histories of respiratory symptoms prior to death, many had an increased tracheal internal perimeter and an increased cartilage length compared to the mean values of the investigators' "normal" population. With greater statistical significance, the membranous trachea mea-

surements were also larger than the mean, but the ratio of cartilage to muscle was reduced. As the proportion of cartilage would signify rigidity, this decreased ratio would imply easier collapsibility of the trachea.

Wailoo and Emery⁸¹ later studied the membranous tracheas of 560 children and found that the transverse muscle was consistently uniformly arranged; however, there was considerable variability in the longitudinal muscle fibers. These fibers are located deep to the transverse fibers and are most consistently found in the lower trachea, suggesting its importance in preventing collapse, particularly in the intrathoracic trachea. The lowest incidence of longitudinal muscle was found in the preterm infants (31.4%) and the highest was found in children > 1 year of age (54.0%), suggesting an increase in the muscle with age.

In a separate study, Wailoo and Emery³² studied 40 tracheas obtained postmortem from children with TEFs and found that the most common abnormality was a deficiency of cartilage with a concomitant increase in the length of membranous muscle. There is a decrease in the normal 4.5:1 ratio of cartilage to muscle in 68% of children with TEF. This resulted in a loss of the normal horseshoe shape, potentiating the anteroposterior collapse of the walls during respiration. Endoscopic correlations of the findings of Wailoo and Emery³² have been observed in patients with TM and fistula.⁸²

Mair and Parsons⁸ have proposed a "major airway collapse" (MAC) classification system that incorporates histologic features and endoscopic appearance. MAC type 1 would represent congenital tracheal collapse, without airway compression. This group of patients would therefore include premature infants, those with EA, TEF, the mucopolysaccharidoses, and Larsen syndrome. MAC type 2 would be reserved for those patients with tracheal collapse caused by extrinsic compression, such as that from vascular anomalies, cysts, teratomas, hemangiomas, thymus enlargement, or goiter. MAC type 3 refers to acquired malacia arising from prolonged ventilatory support, tracheotomy, or severe tracheobronchitis. Mair and Parsons⁸ thought that the term *tracheomalacia* should be reserved for cases in which the posterior membranous wall is widened and its ratio to the anterior tracheal cartilaginous wall approaches the 2:1 ratio.

Incidence and Natural History

The incidence of the congenital form of TM in children at large is not commonly reported, but one study⁸³ has estimated it to be 1 per 1,445 infants. The incidence of the congenital form of TM caused by

associated congenital diseases parallels the incidence of those diseases and is therefore smaller. In a retrospective study of 664 diagnostic bronchoscopies performed in a university setting, 15.4% of infants studied had evidence of TM.²¹ However, in children ≤ 3 years old undergoing bronchoscopy specifically for respiratory distress, TM has been shown to be present in up to 30% of patients.⁸ In a study of 50 infants with TM, 24 (48%) were considered to have primary TM and 26 (52%) to have secondary TM.²¹ Ninety-six percent of the infants with the secondary TM were premature infants with respiratory distress syndrome requiring prolonged mechanical ventilation.²¹

With the advent of modern neonatal respiratory care, a growing number of premature infants are being treated for respiratory distress syndrome and bronchopulmonary dysplasia.⁶⁴ In addition, the number of bronchoscopic procedures in the United States has increased greatly over the past decade, resulting in an increase in the number of documented cases of TM. The number of false-positive cases that this annual increase reflects is unclear, as the techniques that are used for diagnosis have not been standardized.

TM is associated with substantial morbidity and mortality. It may go unrecognized or misdiagnosed as asthma or other respiratory conditions, thereby contributing to the morbidity of the disease. The clinical severity of TM and TBM ranges from mild to life-threatening.^{8,84,85} The mortality rate from severe TM is as high as 80%.⁸⁵

Symptoms

Classically, the signs and symptoms of TM have been described^{23,36,86} as occurring not at birth but instead appearing insidiously during the first weeks to months of life. A more recent study⁸ noted that the first respiratory symptoms of congenital TM occur at birth in as many as 95% of infants. Expiratory stridor and cough, often described as barking or brassy, are the most commonly reported symptoms^{16,87} (Table 2). If there is malacia of the extrathoracic trachea, inspiratory stridor can be found. The cough is most likely caused by the juxtaposition of the anterior and posterior walls of the trachea, resulting in recurrent vibrations and irritation of the airway.⁸⁸ Affected children may display noisy, medium-pitched to high-pitched breathing. In addition, recurrent respiratory distress,³⁶ wheezing,^{21,89} cyanosis,⁸⁶ spontaneous hyperextension of the neck,^{12,29,49,90} and breath-holding spells⁹¹ have been reported. The “bagpipe sign,” an expiratory sibilant note that persists after the end of visible expiration, also has been described.⁹²

Table 2—Symptoms of Pediatric Tracheomalacia

Stridor
Barking cough
Respiratory distress
Wheeze
Anoxic spells
Cyanosis
Bradycardia
Tachyarrhythmias
Spontaneous hyperextension of the neck
Prolonged expiratory phase
Breathholding spells
Failure to thrive
Increased work of breathing
Sternal, substernal, and intercostal retractions
Recurrent pulmonary infections
Reflex apnea
Respiratory arrest
Cardiac arrest

Sternal, substernal, and intercostal retractions^{12,25,39} can be seen as the work of breathing increases. Symptoms may be exacerbated by activities that increase the child’s respiratory efforts, including coughing, feeding, and crying.⁸ These activities can increase intrathoracic pressure until the extraluminal pressure exceeds the intraluminal pressure and the trachea collapses. Most of these infants have impaired clearance of secretions as a result of luminal closure during cough.²³ Squamous metaplasia⁹³ and impaired mucociliary clearance develop, which contributes to the development of respiratory infections and recurrent pneumonia.⁹⁴ It is important to mention that airway obstruction can occur with anesthesia both in patients known to have or suspected to have TM⁹⁵ and in patients who were previously asymptomatic.^{96,97}

Infants with TM, especially those with vascular compression, are often described as having “feeding difficulties.” These difficulties include varying degrees of dysphagia, regurgitation, cough, and cyanosis, and are thought to be secondary to anatomic and reflex mechanisms.¹⁶ When the trachea is compressed by a full esophagus, intermittent respiratory obstruction⁹⁴ and arterial desaturation²³ can occur, interfering with normal feeding and resulting in poor weight gain.⁹⁸ These children may continue to feed despite cyanosis, therefore parents are instructed to interrupt feeding at frequent intervals.²³

“Reflex apnea,” a term coined by Fearon and Shortreed,⁴⁹ is also called “death attacks,” “dying spells,” and “apneic spells” in the literature.^{6,21,98} The process is thought to be a reflex that is triggered when the trachea is stimulated with secretions or a bolus of food in the esophagus, leading to respiratory arrest. In fact, affected infants cease respiration during bronchoscopy through the same reflex mech-

anism. In 1978, Davies and Cywes⁹⁹ reported 15 respiratory arrests in a patient with repaired EA, distal TEF, and TM. These respiratory arrests can lead to cardiac arrest,^{23,100} and up to two thirds of children with reflex apnea die from their disease.⁸

A clinical severity rating has been proposed for children with TM caused by TEF,^{29,77} and it has been applied to all patients with TM.¹⁰¹ Children with "mild" cases have respiratory difficulties associated with infectious processes such as croup or bronchitis. These children often have difficulties with retained secretions. Children with "moderate" cases present with more of the classic findings, including stridor, wheezing, recurrent respiratory infections, and even cyanosis associated with exacerbations. Children with "severe" cases present with stridor during tidal breathing, marked sputum retention, and upper airway obstruction, reflex apnea, and even cardiac arrest.

Diagnosis

TM and TBM must be differentiated from difficult-to-control asthma, intraluminal obstruction, foreign body aspiration, and other diseases. One must have a high index of suspicion for the disease. As Gupta et al¹⁸ suggested > 30 years ago, the uncommon diagnosis of TM may be due to our failure to suspect it. Sotomayor et al⁸⁶ reviewed a series of children with TM in which the mean delay from symptom onset to correct diagnosis was 6 months. Mair and Parsons⁸ found similarly that the delay from the onset of symptoms to diagnosis ranged from 1 to 144 weeks, with a mean of 37 weeks in their series of 38 infants and toddlers. Blair et al²³ reported that the mean age of treatment in their 25 patients with TM and TBM was 7 months, but the range was 1 to 96 months.

Many methods have been used through the years to diagnose TM. Obtaining an adequate history and performing a physical examination are paramount. If the condition is mild enough, pulmonary function testing may be helpful. The flow-volume loop classically reveals flow limitation on the expiratory component and a reduced midexpiratory/midinspiratory ratio.¹⁰²

Radiographs (including comparative inspiratory and expiratory views),¹⁷ tomograms,⁴ tracheograms or bronchograms,^{4,16} and fluoroscopy⁴ have all been used in the diagnosis of TM. In the 1970s, many authors^{103,104} thought that all children with stridor should be evaluated radiographically. The most recent data suggest that the sensitivity of plain radiographs for diagnosing TM is only 62%, using microlaryngoscopy and bronchoscopy as the reference standards.¹⁰⁵ In addition to plain radiography, bar-

ium esophagography is useful for evaluating associated disease processes, including TEF, EA, and reflux disease.

Prospective studies have evaluated the value of CT scans in diagnosing airway lesions in children. Frey et al¹⁰⁶ found 13 airway abnormalities by endoscopic evaluation, 11 of which (84.6%) were also found by CT scan. This high sensitivity coupled with the fact that CT scanning is rapid, noninvasive, and often requires no sedation in children, has led to its use as an initial test in those children with stridor or suspected TM. In the past decade, helical CT scanners, as well as multidetector helical CT scanners, have been developed. The speed of multidetector scanners, which permit imaging of the entire central airways in only a few seconds, is particularly appealing for use in the pediatric population.¹⁰⁷ Although still exposing the patient to ionizing radiation, strict adherence to pediatric guidelines for reducing the CT scan dose provides high-quality images without the use of excessive radiation exposure.¹⁰⁸ Moreover, because of the inherently high contrast between the air-filled trachea and the adjacent soft-tissue structures, it is likely that even further dose reductions can be employed, as demonstrated in a recent animal model study by Boiselle et al.¹⁰⁹ Another advantage of CT scanning is that the data can be reconstructed into two-dimensional and three-dimensional images, including virtual bronchoscopy and external rendering. Although a preliminary report by Konen et al¹¹⁰ has suggested that virtual bronchoscopy may play a complementary role to conventional bronchoscopy in the evaluation of children with central airways disorders, more research is necessary in this area to determine the precise role of this emerging technique.

Although CT scanning provides excellent anatomic detail of the trachea and adjacent structures, this technique exposes patients to ionizing radiation and requires iodinated contrast material administration to fully assess the mediastinal vascular structures. Because of its lack of ionizing radiation, its ability to evaluate vascular structures without iodinated contrast material, and direct multiplanar imaging capabilities, MRI is the preferred method for evaluating extrinsic airway abnormalities, including vascular compression syndromes¹¹¹⁻¹¹³ (Fig 1). As CT scanning and MRI technology evolve, it is likely that they will play an even larger role in imaging the pediatric airway and its surrounding structures.

Despite the amazing advances in imaging the airways, it remains difficult to image the airway during dynamic maneuvers in very small children because of their inability to cooperate with breathing instructions. Thus, for this reason and those described above, many experts still think that diagnos-

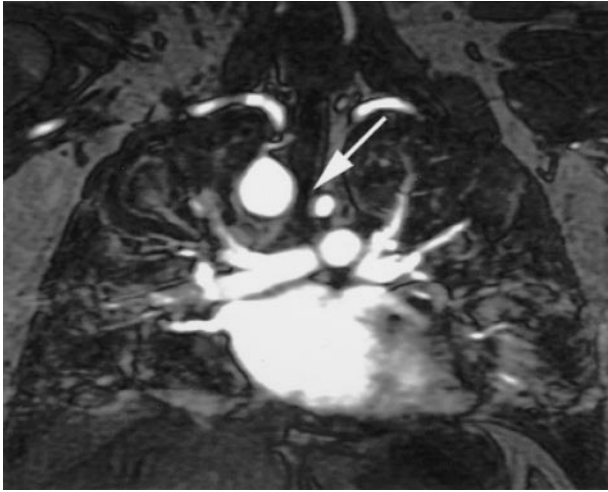


FIGURE 1. MRI of vascular entrapment of the trachea. The arrow refers to the narrowed segment.

tic endoscopy is mandatory.^{29,36,82} We think that endoscopy is an invaluable, essential tool and that it should remain the preferred method for evaluating the airways. This belief is somewhat controversial in pediatric populations because endoscopy is invasive and requires that the child be spontaneously ventilating. If the child is paralyzed, heavily sedated, or receiving positive-pressure ventilation through any means, airway collapse may be missed. Therefore, general inhalation anesthesia, which maintains spontaneous ventilation without endotracheal intubation, is often employed. The anesthetic is entrained along with oxygen into the side port of the rigid bronchoscope. Once the vocal cords are inspected and anesthetized with topical agents, the trachea and bronchi are evaluated, with careful attention to their shape, configuration, and mucosal contours. As the anesthesia is reduced and the patient begins to move and cough, the dynamics of the airway can be assessed fully.²⁷

A visualized decrease in the diameter of the trachea of $> 50\%$ is considered to be abnormal. This percentage is based primarily on studies in the 1960s by Wittenborg et al,² who used trachograms to show that changes in the diameter of the trachea were minimal with quiet breathing in healthy children. However, with exertional respiratory efforts, such as crying or struggling, tracheal collapse reduced the diameter to between 20% and 50% of normal. The majority of infants with TM have a $> 75\%$ collapse, with complete tracheal collapse in up to 33% of infants.² In addition to the typical anteroposterior collapse, indistinct tracheobronchial rings are a described finding.³⁶

Treatment

In many children with TM, intervention is not necessary. As the child grows, the tracheal cartilage strengthens and stiffens. The symptoms often resolve in children with mild-to-moderate TM by age 1 year⁷ or 2 years.^{17,47,85} Therefore, conservative therapy in milder cases is preferred,³¹ and includes the treatment of respiratory infections, humidified oxygen therapy, and pulmonary physiotherapy.^{31,87} For children who do not recover spontaneously or who have life-threatening symptoms, a variety of treatment options are available.

There have been many inroads in the treatment of TM in the last 3 decades. In the past, the mainstay of therapy in patients with severe TM was tracheostomy and long-term mechanical ventilation. Pioneering physicians recognized early that standard tracheostomy tubes were not always long enough to stent the involved segment of the trachea. Physicians developed elongated tracheostomy tubes or advanced thin-walled tubes through a standard tracheostomy to mechanically stent the distal trachea.^{16,114–117} The problems with this approach included the need to change the length of the tube as the child grew, recurrent bronchospasm, the negation of the glottic mechanism of increasing intratracheal pressure, and difficult decannulation.⁶⁴ The associated complications of additional tracheal injury and recurrent infections also decreased the popularity of this approach and spurred the search for alternatives. The percentage of infants and children who still require tracheostomy for TM varies from 12 to 62%.^{8,21,31,118,119} In 1994, Jacobs et al²¹ reviewed 50 cases of TM and reported that tracheostomy was required in 75% of premature infants and in 39% of full-term infants. Of those, 71% were able to undergo decannulation after an average of 30 months without further intervention.²¹ In 1992, Duncan et al¹²⁰ reviewed a total of 44 home tracheostomies and found that 14 (32%) were for TM. With the advent and implementation of other forms of therapy, this percentage is likely to decrease.

Continuous positive airway pressure (CPAP) is an effective treatment for infants with moderate-to-severe TM, TBM, or bronchomalacia.^{101,121–125} Bronchoscopy^{121,125} and fluoroscopy⁸⁶ have shown that CPAP maintains airway patency during tidal breathing. By essentially creating a pneumatic stent, CPAP prevents the collapse of the airway throughout the respiratory cycle.

Tidal-breathing flow-volume measurements have been used to evaluate the changes in airway obstruction with the use of CPAP.^{101,123} The level of CPAP is often based on these evaluations, but more commonly it is based on clinical response.^{122,124,127,129}

Kanter et al¹²¹ used up to 19 cm H₂O pressure, and, with the aid of esophageal measurements, found that esophageal pressure did not exceed 3 cm H₂O and that circulation was not compromised. Davis and colleagues¹⁰¹ measured full forced expiratory flow (FEF)-volume curves at CPAP levels of 0, 4, and 8 cm H₂O in infants with TM and in healthy control subjects. In both groups, FVC did not change with increasing levels of CPAP, but inspiratory capacity decreased and functional residual capacity increased. The FEF values at functional residual capacity increase with increasing levels of CPAP, but the FEF values at 50% and 75% of expired volume did not differ with different levels of CPAP or between the groups. The authors concluded that CPAP affects forced flows primarily by increasing lung volume. Panitch et al¹²⁸ agreed with their predecessors that the measurement of tidal mechanics was important in determining the appropriate level of pressure. However, they placed new emphasis on the mechanics during forced expiratory maneuvers (such as coughing and crying) because airway collapse is more likely to occur during such maneuvers.

Despite these advances, CPAP has some disadvantages, including lag in the commencement of oral feedings, retardation of speech and language, and potential developmental delay.^{21,122} Jacobs et al²¹ reported that CPAP was required for an average of 21.4 months by premature infants and 22.0 months by the full-term infants in their series. Depending on the estimated duration of treatment, CPAP can be considered a primary treatment or as an adjuvant to other therapies.¹²²

In patients who have the most severe forms of TM that are unresponsive to medical management or who present with life-threatening symptoms, surgical intervention may be necessary. Indications for surgery include recurrent pneumonia,^{23,87,130} intermittent respiratory obstruction,²³ and the inability to extubate the airway.^{23,87,130,131} Dying spells, the most concerning of all symptoms, is an indication for continued hospitalization and definitive surgical intervention.^{23,76,130}

During the past decade, aortopexy has become the procedure of choice for the treatment of severe TM.^{23,87} Gross and Neuhauser¹² were the first of many investigators^{6,23,24,31,34,94} to describe the use of aortopexy specifically for treating TM caused by a vascular anomaly. In this procedure, the ascending aorta is approached traditionally through a right-sided anterior thoracotomy at the third intercostal space^{23,132} or through alternative routes.^{7,133–136} Traction on the sutures placed in the wall of the aorta juxtaposes it to the undersurface of the sternum, which also pulls the anterior wall of the trachea forward. This mechanical fixation of the aorta widens

the anteroposterior dimensions of the trachea and prevents collapse.^{23,87} It is important to note that aortopexy is not always successful in relieving the collapse,^{23,87} and therefore additional surgical approaches have been devised.^{130,137–141}

Of note, patients with airway malacia warrant special consideration with respect to anesthesia.^{142,143} In the 2003 review by Austin and Ali,¹ the authors point to the following two main goals of the anesthesiologist: preventing airway collapse and air trapping with the use of CPAP/positive end-expiratory pressure; and minimizing cough. The authors discuss¹ the safe and effective use of topical anesthesia, general anesthesia with inhalational agents, general anesthesia with IV agents, endotracheal tubes, and laryngeal mask airways in experienced hands.

External splinting with autologous materials, most commonly a resected rib, and prosthetic materials, such as silastic membrane-reinforced crystalline polypropylene and high-density polyethylene (Marlex; Phillips Petroleum; Bartlesville, OK) mesh, have been used to support the flaccid trachea.^{23,47,74,131,144,145} Support can be provided either by suturing a rigid support directly to the membranous trachea through a posterolateral right thoracotomy or by wrapping the supporting material around three quarters of the tracheal circumference through an anterior cervical or median sternotomy approach.²³ In animal studies¹⁴⁴ and in limited human studies,¹⁴⁶ this procedure did not adversely affect the growth of the trachea. However, it is an invasive procedure that may not adequately treat distal bronchial lesions and may not be tolerated well by patients with complicated conditions.⁸⁷ Treatment with tracheopexy,^{35,147,148} tracheal resection,^{31,149} and tracheal reconstruction¹⁵⁰ have been attempted with limited success.

Internal tracheal stent placement with a silicone prosthesis was first attempted in 1965 by Montgomery.¹⁵¹ Since then, a wide variety of stents have been used, including those made of silicone and of metal.^{64,87,152} The obvious advantages of stents are their less invasive nature and the shorter surgical recovery times. Filler et al¹⁵³ described 16 patients with airway obstruction, 8 of whom had TBM as their primary diagnosis. All eight children were successfully treated with stents, including two children with dying spells.¹⁵³ Furman et al¹⁵⁴ also reported relief of airway obstruction and the liberation from mechanical ventilation with the use of stents; however, the formation of granulation tissue was a common complication, and one death in the series may have been related to stent placement.¹⁵⁴

Metal stents have the advantages of minimal thickness and easy deployment. However, complications and limitations include granulation tissue formation,

difficult removal, death, stent fracture, the need for additional stent placement, migration, and the need to further dilate the stent as the child grows. An advantage of the silicone stents is the relative ease of both the removal of the stent and the deployment of a larger stent if it is required as the child grows. Removability is especially important, as children stand a reasonable chance of becoming asymptomatic once their airways grow. Currently, stents are used in limited situations in which conventional therapy has failed. However, stents currently in development, such as resorbable biopolymer stents,¹⁵⁵ may address the limitations of current stents. With these new developments, stent placement may become a more attractive treatment option in the future.⁸⁷

In conclusion, conservative treatment is preferred in milder cases of TM. Secondary TM can develop if primary TM is treated with tracheostomy, mechanical ventilation, or both. Where conservative measures fail, the therapy must be tailored to the individual patient. To date, no perfect operation or procedure exists for the treatment of TM.

ADULT TM AND TBM

History

In 1897, Czyhlarz¹⁵⁶ was the first to describe the postmortem finding of an unusually large trachea and bronchi. The first clinical report of isolated tracheal enlargement in an adult was by Mounier-Kuhn¹⁵⁷ in 1932. Lemoine¹⁵⁸ was the first to use bronchoscopy to document acquired tracheal enlargement in the adult in 1949. Additional case reports^{159–161} of TM in adults began to appear in the 1950s. Ferraris¹⁶¹ described two patients with acquired TM who both reported “expiratory dyspnea,” the inability to clear secretions, and recurrent respiratory infections. Both had been labeled and treated as asthmatic patients.¹⁶¹ Herzog and Nissen¹⁶⁰ described five patients with acquired TM, all of whom had stridor, cough, and expiratory obstruction. Endoscopically, all five patients had tracheal obstruction caused by the ballooning of the posterior membranous wall into the tracheal lumen during expiration. Four patients were treated surgically by placing a bone graft in the membranous trachea to prevent collapse.¹⁶⁰

Classification

A few classification schemes for adult TM have been proposed. Classification by macroscopic clinical findings is sometimes employed, with lateral wall narrowing being called the “saber-sheath type” or

“fissure shape,” and the anteroposterior wall narrowing being referred to as the “crescent type” or “scabbard shape.”^{17,162,163} Some clinicians have included a third macroscopic designation for the “circumferential” narrowing¹⁹ or have labeled this appearance as a combination of the crescent and saber-sheath types.¹⁶⁴ Feist et al⁴ and others¹⁶³ classified TM into congenital forms (as in the Mounier-Kuhn disease) and acquired forms, such as those resulting from tracheostomy, chest trauma, chronic irritation, inflammation, mechanical anatomic factors, or malignancy. We have adhered to the latter classification schema, as we did in the pediatric section (Table 3).

Congenital or Primary Forms

In the pediatric section, we discussed the congenital diseases, such as polychondritis, that weaken the trachea. Some of these conditions allow the survival of affected children into adulthood, therefore these adults would be considered to have congenital TM. There is one additional congenital condition that is not seen in children, but is found in the adult population. Idiopathic giant trachea, or tracheomegaly, is a rare condition that is characterized by atrophy of longitudinal elastic fibers and thinning of the muscularis mucosa.¹⁶⁵ This combination allows the trachea and central bronchi to dilate, with a transition to the normal diameters of the peripheral airways.¹⁶⁶

Table 3—Classification of Adult TM

TM	Description
Primary (congenital)	Genetic, such as polychondritis (also see pediatric table) Idiopathic “giant trachea” or Mounier-Kuhn syndrome
Secondary (acquired)	Posttraumatic Postintubation Posttracheostomy External chest trauma Post-lung transplantation Emphysema Chronic infection/bronchitis Chronic inflammation Relapsing polychondritis Chronic external compression of the trachea Malignancy Benign tumors Cysts Abscesses Aortic aneurysm Vascular rings, previously undiagnosed in childhood

Idiopathic giant trachea bears the name of the clinician, Mounier-Kuhn,¹⁵⁷ who originally described the radiographic and endoscopic appearance of a giant trachea in a patient with recurrent lower respiratory tract infections. As of 1988, 82 cases of Mounier-Kuhn disease had been described in the literature,¹⁶⁷ and to date, well over 100 cases have been described. The number of recognized cases has increased with the increased awareness of the disease and with the advent of CT scanning because the condition may not be apparent on plain chest radiographs. The diagnosis can be made when the right mainstem, left mainstem, and trachea exceed 2.4, 2.3, and 3.0 cm, respectively, as these measurements represent 3 SDs above the upper limit of normal in adults.¹⁶⁸ The cause is unknown; however, in 1965, Johnston and Green⁴¹ described tracheobronchomegaly in five patients with a documented familial occurrence. Whether this occurrence constitutes a primary pathology or a predisposition to injury and subsequent development of a giant trachea is unknown. Some believe it is an acquired disease,¹⁶⁹ based on its rarity, association with chronic respiratory infections, and its delay in onset. The majority of patients have few if any symptoms in childhood and adolescence, but there are exceptions.¹⁷⁰ Mounier-Kuhn syndrome is diagnosed in up to 75% of patients after age 28 years, with the majority diagnosed in the third or fourth decade of life.¹⁶⁵

In Mounier-Kuhn syndrome, secretions are poorly mobilized, leading to the chronic accumulation of secretions, recurrent infections, bronchiectasis, and even pulmonary fibrosis.¹⁶⁵ Tracheal diverticuli form secondary to the increased global compliance of the tracheal wall and the development of redundant membranous tissue.¹⁶⁷ In 1973, Himalstein and Gallagher¹⁷¹ classified the disease into three types. Type 1 disease is characterized by relatively subtle, symmetric, diffuse enlargement of the tracheobronchial tree. In type 2 disease, enlargement is more obvious, with diverticula, odd eccentric configurations, or both. In type 3 disease, the diverticula or sacculations extend to the distal bronchi.

Acquired or Secondary Forms

A variety of processes can cause secondary TM and TBM in adults (Table 3). A sentinel review article by Feist et al⁴ in 1975 incorporated the data from the 1950s and 1960s and described the causes of adult TM. The authors identified tracheostomy or intubation with endotracheal tubes as the most common cause of secondary TM.⁴ Tracheostomy may lead to tracheal stenosis; however, it can also lead to frank weakening of the tracheal wall as a result of the destruction and loss of the supporting

cartilage. This postintubation malacia is most commonly ≤ 3 cm in length and is segmental in nature. Although some injuries heal, factors such as recurrent intubation, the duration of intubation, and the use of high-dose steroids may predispose patients to developing progressive TM. The area of weakness can be seen not only at the stoma site but also at the inflatable cuff site.⁴ Occasionally, an additional abnormality may appear at the point where the tip of the tracheostomy tube impinges on the tissue. Possible causes of tracheal weakness in these areas include pressure necrosis, impairment of blood supply, and recurrent infections, as well as friction on, and inflammation of, the mucosa.¹²⁶ Other forms of posttraumatic TM may result from any injury causing a loss of cartilage from the trachea, including external trauma and surgery, such as lung transplantation.¹⁷²⁻¹⁷⁴ The TM that occurs in these situations should be differentiated from the less collapsible areas of anastomosis that may occur from trauma or surgery, which does not result in a weakness of the trachea.

Other authors also have suggested^{175,176} that chronic inflammation and irritants, such as cigarette smoke, are the most important contributors to the development of TM. A substantial proportion of patients with severe emphysema have some degree of malacia. The weakening of the tracheal wall may be related to the recurrent injury from cigarette smoke that leads to the emphysema, or it may merely be an extension of the peripheral hypermobility of the airways. Patients with chronic bronchitis may also have TM, which is thought to be secondary to the insult of recurrent infections, with or without cigarette smoking.

Additional etiologies for secondary TM exist. Chronic compression of the trachea resulting in TM most commonly results from benign mediastinal goiter,¹⁷⁷ but it can also result from other sources of compression, including malignancies, abscesses, and cysts.^{4,176} The literature also contains several reports^{19,178,179} of relapsing polychondritis, a disease that is characterized by recurrent inflammation and the destruction of the cartilaginous structures (tracheobronchial chondritis). In fact, respiratory tract involvement in relapsing polychondritis occurs in up to 56% of cases, but the respiratory symptoms are found on presentation in only 14% of cases.¹⁸⁰ Patients with respiratory complications have a worse prognosis and poorer response to corticosteroids.¹⁸⁰⁻¹⁸² Last, 26 cases of vascular rings have been diagnosed in adults, including double aortic arch and right aortic arch with an aberrant left subclavian artery and ligamentum arteriosum.¹⁸³ As in children, these vascular malformations can cause TM and respira-

tory symptoms, including dyspnea, bronchitis, recurrent pneumonia, and stridor.¹⁸³

Histopathologic Characteristics

Little is known about the histologic changes occurring in adult TM. In autopsy studies,^{159,184} the pars membranacea is dilated and flaccid, with anteroposterior narrowing of the bronchial lumen. Kierner et al¹⁸⁵ described atrophy of the longitudinal elastic fibers of the pars membranacea, as did Herzog.¹⁸⁶ Ikeda et al¹⁸⁷ also described "fragmentation" of the tracheal cartilage. Jokinen et al¹⁷⁶ also noted that the number of longitudinal fibers in the pars was clearly reduced throughout the entire length of the trachea above the bifurcation in one patient with TM compared to that in a control population. The number of longitudinal fibers did not differ from that of control subjects at the level of bifurcation or at the beginning of the mainstem bronchi.¹⁷⁶ In this study, the total mucopolysaccharide, elastin, and collagen content in the cartilage of the trachea and bronchi were also similar.¹⁷⁶

Incidence and Natural History

The occurrence of TM and TBM in the adult population is not uncommon. Although the Mounier-Kuhn form of the disease may have a genetic basis, the overwhelming majority of adults with TM and TBM have the acquired or secondary forms of the diseases. The true incidence of TM and TBM in adults is unclear because reports have been based on selected populations, instead of the population at large. In the late 1970s, Nuutinen⁵ and Jokinen et al¹⁷⁶ greatly expanded the literature on acquired adult TM. Their data indicated that acquired TM was a disease of the middle-aged and elderly, most commonly seen in men > 40 years of age. Jokinen et al¹⁷⁶ reported finding TM in 50 of 214 patients (23%) with a history of chronic bronchitis who were examined bronchoscopically.¹⁷⁵ Herzog¹⁸⁶ reported TBM in 16 of 1,500 patients (1%) undergoing bronchoscopy for various respiratory symptoms. In 1977, Jokinen et al¹⁷⁶ also reported bronchoscopic findings for 2,150 Finnish patients with a range of symptoms and found that 94 patients (4.5%) had some form of malacia. Of these 94 patients, TM was diagnosed in 21 (22%), TBM in 59 (62%), and isolated bronchomalacia in 14 (15%). TM was seen much more commonly in men (82%) compared to women (18%), possibly reflecting the increased smoking prevalence in men at the time the study was conducted. It was seldom found in individuals without some evidence of obstructive lung disease.¹⁸⁸ The most recent data on the incidence¹⁸⁷ of airway collapse are from Japan where the rate of

airway collapse was > 50% in 542 of 4,283 patients (12.7%) with from pulmonary disease who underwent bronchoscopy. In that study, 72% of patients were aged 50 to 80 years.

TM is progressive in some patients.^{5,162,176} Jokinen et al¹⁷⁶ performed repeat bronchoscopies on 17 of their patients with TM and TBM, and found that severity had progressed in 13 patients. Nuutinen¹⁸⁹ reported a longitudinal study of 94 patients with TM and TBM with an average follow-up period of 5.2 years. Of those patients who had undergone repeat bronchoscopy, TM had progressed into TBM in six of nine patients, and bronchomalacia had progressed to TBM in all five patients. In no patient did the malacia improve. Some patients remained stable; however, the conditions of the majority of patients with mild-to-moderate disease worsened.

Symptoms

The main symptoms of TM in adults are dyspnea, cough, sputum production, and hemoptysis.⁵ These symptoms are nonspecific and are often attributed to emphysema, chronic bronchitis, cigarette smoking, or asthma. In fact, the patients may have coexistent emphysema, chronic bronchitis, or, less commonly, asthma or bronchogenic carcinoma.⁵ These patients may exhibit evidence of collapse of the upper airway during forced exhalation. There may be inspiratory wheezing or stridor. An associated barking cough, which has been likened to a barking seal, has also been reported. In addition to the more nonspecific symptoms, patients may also report dyspnea,¹⁹⁰ episodic choking, chronic cough,¹⁹⁰ hemoptysis,¹⁹¹ recurrent pulmonary infections,¹⁹⁰ and even syncope associated with forced exhalation or cough.^{164,192,193} Unmasking of the disease with anesthesia¹⁹⁴ and progressive hypercapnic respiratory failure¹⁹⁵ have been reported. Some patients are asymptomatic until stressed by infection such as bronchitis or pneumonia. In intubated patients, TM may not be evident because positive-pressure ventilatory support keeps the airway open. Once the positive pressure is removed, the patient may experience respiratory distress, wheezing, and apparent stridor. Patients may be reintubated as a result of these symptoms, and unexplained extubation failure should prompt evaluation for TM.

Diagnosis

The trachea and bronchi are normally flexible and compliant, and their diameters change during normal respiration. During inspiration, the airways dilate and lengthen, and during expiration, they narrow and shorten. Weakening of the tracheal wall accentuates these changes, and excessive changes in diam-

eter may deform segments of the trachea, the entire trachea, and even the left and right mainstem bronchi. Because this deformation is a dynamic process that is accentuated by forced expiration, routine anteroposterior and lateral chest radiographs often show no abnormality. However, if TM is not isolated, but is caused by compression from other structures, such as mediastinal goiter, this deformation may be seen on plain radiographs.⁴

In an earlier time, tracheograms and bronchograms, which required the introduction of radiopaque material into the trachea, were performed to outline the bronchial tree and to evaluate the size of the structures.⁴ Cinetracheograms were used in the hopes of seeing “tracheal flutter,” and fluoroscopy was also used to estimate tracheal diameter. However, due to improved sensitivity, the convention became direct visualization by bronchoscopy to document a narrowing of at least 50% in the sagittal diameter. Some authors¹⁸⁹ further classified the severity of malacia into mild, moderate, and severe. The malacia is deemed to be mild if the obstruction during expiration is to one half of the lumen, moderate if it reaches three quarters of the lumen, and severe if the posterior wall touches the anterior wall.¹⁸⁹

Today, bronchoscopic visualization of dynamic tracheal or bronchial collapse remains the reference or “gold standard” for diagnosing TM. Although some studies use straining, coughing, and other maneuvers to elicit airway wall collapse, the expiratory effort to achieve collapse has never been standardized. Endoscopic visualization may be performed with either a rigid or a flexible bronchoscope. Flexible bronchoscopy is generally preferred be-

cause the patient is able to breathe spontaneously and follow commands to perform deep breathing, forced exhalation, and cough maneuvers to elicit the collapsibility of the airways (Fig 2). On direct visualization, the membranous trachea is widened and may even be redundant. There is obvious collapse of the airway during forced expiration, and in some cases the airway lumen is completely obliterated as the membranous trachea collapses to the cartilaginous rings.

Emerging data^{196,197} suggest that dynamic CT scan images, although not the reference standard, are useful in diagnosing TM. Stern et al¹⁹⁸ published data on the normal trachea during forced expiration. They defined the normal range of intrathoracic tracheal diameters and cross-sectional areas during forced maneuvers, and showed that tracheal narrowing was about 80% in a patient with TM vs 35% in 10 healthy men. They then recommended using a cutoff of $\geq 70\%$ narrowing on forced expiration as a diagnostic threshold for TM.¹⁹⁸ Most other investigators, however, have employed the criteria of $> 50\%$ narrowing as a criteria for TM.^{191,196,199–203} Future studies of dynamic tracheal measurements involving a larger number of subjects of varying ages and both genders are necessary to more fully elucidate the normal range of tracheal collapsibility in the general population.

Although a diagnostic criterion of $> 50\%$ reduction of the cross-sectional area of the trachea during expiration has been widely used in both bronchoscopy and CT scan studies, it is important to note that the use of end-expiratory imaging rather than dynamic expiratory imaging may require a lower threshold criterion for diagnosing TBM. In this

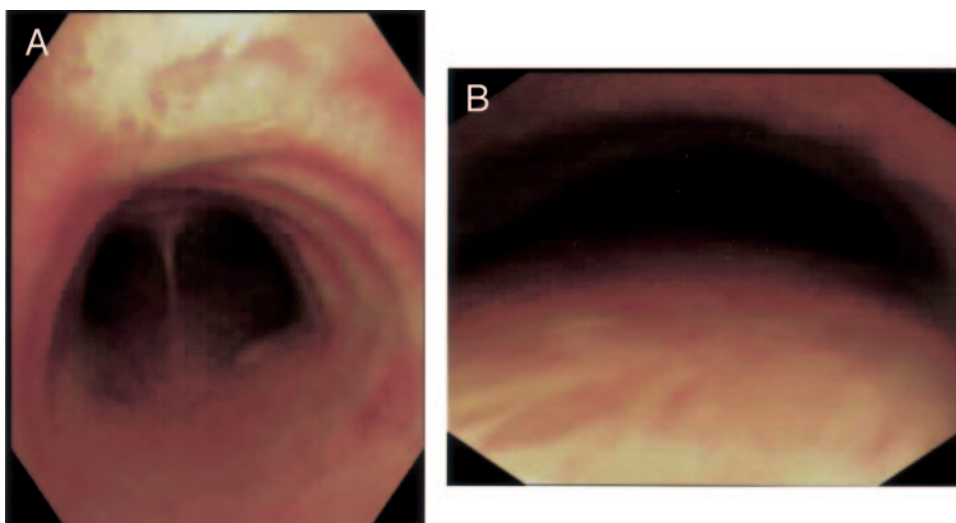


FIGURE 2. Bronchoscopic view of TM. *Left, A:* normal status during inhalation. *Right, B:* near total collapse during quiet exhalation.

regard, Aquino et al¹⁹⁷ compared cross-sectional area and coronal and sagittal diameters of the trachea between inspiration and end-expiration in 10 patients with TM and 23 healthy patients. Receiver operating characteristic curve analysis revealed that if a change between inspiration and expiration in the upper trachea exceeded 18% and the change in the midtrachea exceeded 28%, the probability of TM was between 89% and 100%.

The development²⁰⁴ of multidetector CT scanners, which permit imaging of the entire central airways in only a few seconds, allows for volumetric imaging of the airways during a single, dynamic, forced exhalation maneuver. Using this method, Gilkeson et al¹⁹⁶ reported agreement between dynamic expiratory CT scan findings and collapsibility seen during bronchoscopy. Similarly, in a 2003 study that included 10 patients with bronchoscopically proven TBM, Zhang et al²⁰³ showed that dynamic expiratory CT scanning is highly sensitive for detecting malacia. These investigators also showed that a low-dose CT scan technique is comparable to a standard-dose technique for measuring the tracheal lumen during the dynamic expiratory phase of respiration. One year later, Zhang et al²⁰⁵ used dynamic expiratory volumetric CT scanning to compare 10 patients with bronchoscopically confirmed TM to 10 control subjects. Air trapping was seen at a higher frequency (TM patients, 100%; control subjects, 60%) and was more severe in the patients with TM.²⁰⁵

Suto and Tanabe²⁰⁶ used dynamic MRI during forced expiration and cough to compare the collapsibility of the trachea in patients with TM to that of healthy subjects by using a “collapsibility index,”

originally proposed by Shepard et al.²⁰⁷ These investigators showed that a coughing maneuver elicited a significantly greater degree of collapse than forced end-expiration. Because of its lack of ionizing radiation, MRI has the potential advantage of allowing repeated assessments of the trachea during multiple respiratory maneuvers. Future studies comparing CT scanning and MRI are necessary to determine the relative sensitivities and specificities of these methods for diagnosing TM with conventional bronchoscopy as the “gold standard.”

Although still in their youth, multiplanar and three-dimensional CT scan reconstructions, including virtual bronchoscopy, are promising imaging methods for the evaluation of TM. Although axial images suffice for assessing the airways that are perpendicular to the axial plane (*eg*, the trachea and bronchus intermedius), they are less than ideal for evaluating airways that course obliquely (*eg*, the mainstem bronchi). Paired end-inspiratory and dynamic expiratory virtual bronchoscopy images provide an important complement to axial CT scan images for these portions of the airway. Interestingly, in the study by Gilkeson et al,¹⁹⁶ virtual bronchoscopy images occasionally obviated the need for conventional bronchoscopy in patients who had relative contraindications to this procedure. With regard to multiplanar CT scan reformations, paired end-inspiratory and dynamic-expiratory sagittal images are helpful for displaying the craniocaudal extent of excessive tracheal collapse at end-expiration (Fig 3).

It is important to pay careful attention to technical parameters when performing CT scan examinations for assessing TM. For example, Burke et al²⁰⁸ described a series of patients with airway obstruction

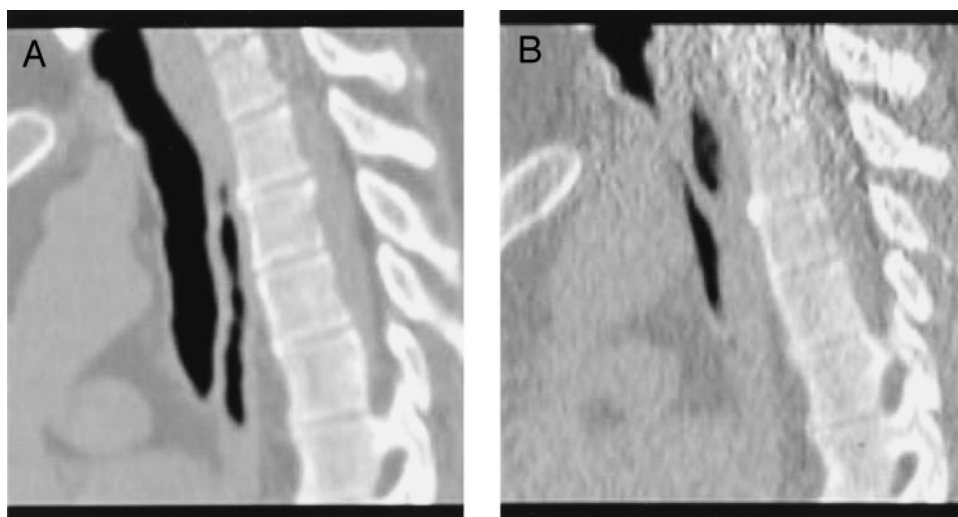


FIGURE 3. Two-dimensional CT scan airway reconstruction of the trachea. *Left, A:* the trachea during inhalation. *Right, B:* segmental tracheal collapse (arrow) during exhalation.

evaluated by virtual endoscopy and bronchoscopy in which patients underwent imaging only at end-inspiration. Although the virtual technique was excellent at defining and measuring fixed lesions, it missed half of the laryngeal TM cases. The low sensitivity for detecting malacia in this study likely relates to the fact that these investigators performed CT scanning only at end-inspiration. Their results underscore the need to perform dual-phase (end-inspiratory and dynamic expiratory imaging) for assessing TM. Future studies of dual-phase virtual bronchoscopy are necessary to determine the precise role of this emerging technology in the diagnosis of TM.

Pulmonary function studies may be useful in evaluating a patient with suspected TM, but they are not diagnostic. Spirometry commonly reveals obstruction in proportion to the severity of malacia¹⁸⁹; however, this is not a universal finding.¹⁹⁶ The pattern is usually that of a decreased FEV₁ and a low peak flow rate with a rapid decrease in flow (Fig 4). Airway resistance is almost always elevated.¹⁹ There is relative preservation of the shape of the inspiratory limb.²⁰⁹ Herzog,¹⁸⁶ Gandevia,²¹⁰ and Campbell et

al¹⁸⁴ have reported that patients with tracheobronchial collapse frequently have a characteristic pattern on forced expiratory spiograms. In addition to a near complete absence of the usual sloping phase of the mid-portion of the curve, there may be a “break” or notch in the expiratory phase of the flow-volume loop. This break, first described by Koblet and Wyss,²¹¹ is presumed to be the point of MAC after the emptying of dead space air volume. It is also seen in moderate-to-severe emphysema patients who may or may not have TM, and it is difficult to determine the relative contributions of lung disease and TM if the conditions coexist.²⁰⁹ Flow oscillations, defined as a sequence of alternating decelerations and accelerations of flow, are often seen on the expiratory curve. In a large survey²¹² of 2,800 flow-volume loops, the incidence of these oscillations was 1.4%. These oscillations can be caused by redundant pharyngeal tissue, as in obstructive sleep apnea syndrome, structural or functional disorders of the larynx, neuromuscular diseases, and TM.^{213,214} Campbell and Faulks¹⁸⁴ showed by esophageal balloon pressure measurements that the intrathoracic pressure was still rising sharply, while the expiratory velocity began falling rapidly from its peak. This condition is an exaggeration of the normal pressure-flow relationship observed during the development of flow limitation. Decreased peak flow is thus characteristic of the obstruction and hypercollapsibility of the airways.

Treatment

Many adults with TM and TBM do not require therapy because the finding may be incidental, and these diseases may not be causing symptoms. In a patient with symptomatic TM, care is initially supportive, unless the situation is emergent or progressively worsening. As TM frequently occurs in patients who also have COPD, the obstructive disorder optimally should be treated first. Bronchospasm must be controlled as it results in large pressure swings in the thorax, thereby worsening the degree of collapse of the malacic tracheal segments. This increased airway resistance and work of breathing can lead to respiratory failure. Once COPD has been controlled, a functional pulmonary baseline should be documented so that any response to an intervention for TM or TBM can be objectively evaluated.

If conservative measures fail, or if the patient is in critical condition, noninvasive, positive-pressure ventilation can be used in the short term to keep the airway open and to facilitate secretion drainage.¹⁷⁹ Ferguson and Benoist¹²⁶ have reported that nasal CPAP ventilation increases functional vital capacity and that increased levels of CPAP reduce dynamic

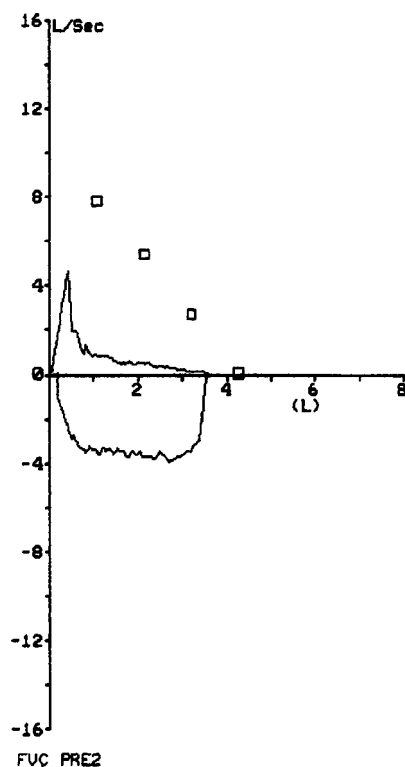


FIGURE 4. Classic flow-volume loops for TM. There is a rapid decline in the maximal expiratory flow after a sharp peak associated with the collapse of central airways due to negative transmural pressure. Normal inspiratory profile is associated with dilation of the central airways during treatment with positive transmural pressure.

airway collapse. The notching on the flow-volume loop indicating airflow obstruction was abolished with the use of CPAP. In the hospital, the patient might require therapy with continuous nasal pressure for a short “recovery” time before transitioning to intermittent use until it is no longer needed.

In selected patients, surgery may be employed. Tracheostomy alone may be effective because the tracheostomy tube might either bypass the malacic segment or the tube itself might splint the airway open. If the patient has generalized and extensive TM, a longer tube may be necessary, as most of the more commonly used tubes are too short to prevent distal collapse, despite providing adequate proximal stenting. A tracheostomy also provides easy access for treatment with positive-pressure ventilation if required to maintain an open airway. Unfortunately, as in the pediatric population, tracheostomy may aggravate the underlying disorder and is, therefore, not a first-line treatment.

Herzog and Nissen¹⁶⁰ and Nissen²¹⁵ were the first to suggest surgical support for the pars membranacea by using a bone graft. Subsequently, a variety of prosthetic and autologous materials have been used as external stents.^{159,216,217} Amedee et al²¹⁸ described 16 patients with TM who were treated with tracheal implantation of from one to three biocompatible ceramic rings. The procedure was successful in all patients, and reintubation or tracheostomy was not necessary in the 6.4 years of follow-up. Additionally, three patients who had been tracheostomy-dependent prior to the procedure tolerated decannulation after the surgery.

Recently, surgical placcation of the posterior wall of the trachea with crystalline polypropylene and high-density polyethylene mesh has received attention.^{187,209,219} In that procedure, access is obtained through a right posterolateral thoracotomy, and the

mesh is fashioned into a 2.5-cm wide strip, which is sutured to the posterior membranous wall. Thereafter, 2-cm sheets of mesh can then be sutured to the right and left mainstem bronchi. At our institution, this procedure is offered to patients who are good surgical candidates and in whom central airway stenting has improved symptoms. Conventional resection and reconstruction can be considered for treatment of focal malacia of the trachea. Last, although tracheal replacement has been talked about for > 50 years, to date no reliable substitute has been found.²²⁰

An array of stents can be used to keep the airway open mechanically.^{87,221} Early attempts at stent placement for TM used stents and tubes that were designed for other purposes, namely, tracheostomy or esophageal intubation.^{222,223} As in pediatric patients, both rigid bronchoscopy and fluoroscopic guidance techniques have been used in adults. Some centers have also reported^{224–227} using flexible bronchoscopy with self-expanding stents in adults.

Metal stents have been used to manage airway obstruction resulting from many causes.^{228,229} They are easily placed by flexible bronchoscopy, are visible on plain radiographs, expand dynamically, and preserve mucociliary function.²³⁰ The most common complications resulting from the use of metal stents are the formation of granulation tissue, which may or may not require intervention, and breakage over time, which can cause severe problems including airway obstruction, airway perforation, and death. Additionally, embedded stents make future options such as surgical interventions difficult or impossible. These disadvantages, coupled with the fact that metal stents can usually not be removed easily, do not make them a first choice for patients with TM. Silicone stents, on the other hand, are easily inserted, repositioned, and removed. Placing these stents re-

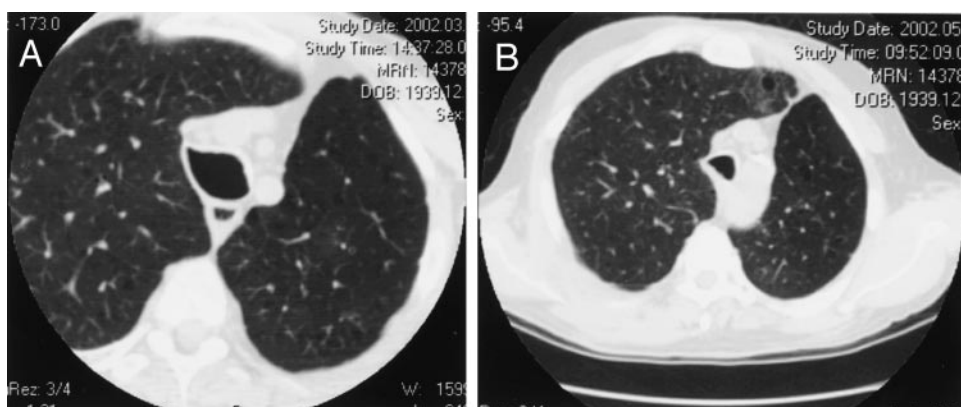


FIGURE 5. CT scan images of a patient with TM. *Left, A:* prior to surgical intervention. *Right, B:* after surgical tracheoplasty, demonstrating a trachea that is normal in shape and size.

quires rigid bronchoscopy and general anesthesia. Although silicone studs on the surface of the stent retard migration, stent migration is still possible and may be heralded by a new cough. This problem requires direct visualization and repositioning, removal, or replacement of the stent. Hybrid stents and biodegradable stents are now being developed, but their utility for this disorder has not yet been evaluated.

Both subjective and objective means have been used to evaluate the efficacy of stent placement for benign airway stenoses. TM is included in many of these series, but there are no large series on TM alone. To describe the benefits of stent placement, clinicians have used improvement of respiratory symptoms,^{173,229,231-233} clearing of infectious processes,^{231,232,234,235} and lack of stent complications^{174,234,235} as end points. Researchers have also used bronchoscopic techniques²³¹⁻²³⁶ and imaging techniques^{232,233,236} to show stent patency as a marker of success.

Most patients report immediate improvement in their respiratory symptoms once the stent is placed.^{173,225} Stents can immediately improve airflow dynamics in patients with benign airway obstruction, including TM,^{172,174,225,231,236-241} but success has not been universal.²⁴² Gotway et al¹⁷³ also reported long-term pulmonary function data with stents placed for both stenotic and malacic lesions. At a mean of 15 months after stent placement, values for FEV₁, midexpiratory phase of FEF, and peak flow parameters had declined, despite the patients' ongoing subjective improvement. The long-term improvement for the TM patients with relapsing polychondritis and idiopathic was better in the series by Gotway et al¹⁷³ than it was in that of 11 patients with TM due to lung transplantation. This has been described previously²⁴³ and is not surprising, because 7 of the 11 patients in the study described previously received a single lung transplant for emphysema (the native lung would contribute to the degree of airflow obstruction). O'Donnell et al²⁴² measured tracheal transmural pressure with esophageal balloons, assessed the cross-sectional shape of the trachea, and measured the critical pressure required to produce maximum expiratory flow in TM patients before and after stenting. They hypothesized that the critical pressure for flow limitation occurs before central airway collapse. In such circumstances, stenting the airway is unlikely to improve maximal expiratory flow. Therefore, a low critical pressure may be a marker for therapeutic failure. If airway stenting does not improve symptoms or the functional baseline of the patient, the stents should be removed to avoid any stent-related complications. At our institution, airway stenting is

used mainly to identify the individual who is most likely to benefit from permanent or surgical airway stabilization. If improvement is present and the patient is a good surgical candidate, surgical tracheoplasty may be a preferred goal (Fig 5). If the patient improves but declines surgery, long-term stenting can be utilized, most commonly with silicone stents. Very rarely will metal stents have a role in the long-term management of this benign disorder. An algorithm of our approach to the patient with TM is outlined in Figure 6.

CONCLUSION

TM and TBM are becoming more commonly recognized and treated in children and adults. The causes and, therefore, the treatments vary, so a working knowledge of the options is important. Noninvasive imaging technology is increasingly being employed for diagnosis, and novel treatments, such as definitive surgical placcation and stabilization with removable stents, are becoming alternatives to conservative interventions, such as CPAP. As a result of the complexity of these conditions and the options for treatment, these patients may best be assessed and managed individually in centers specializing in complex airway disorders.

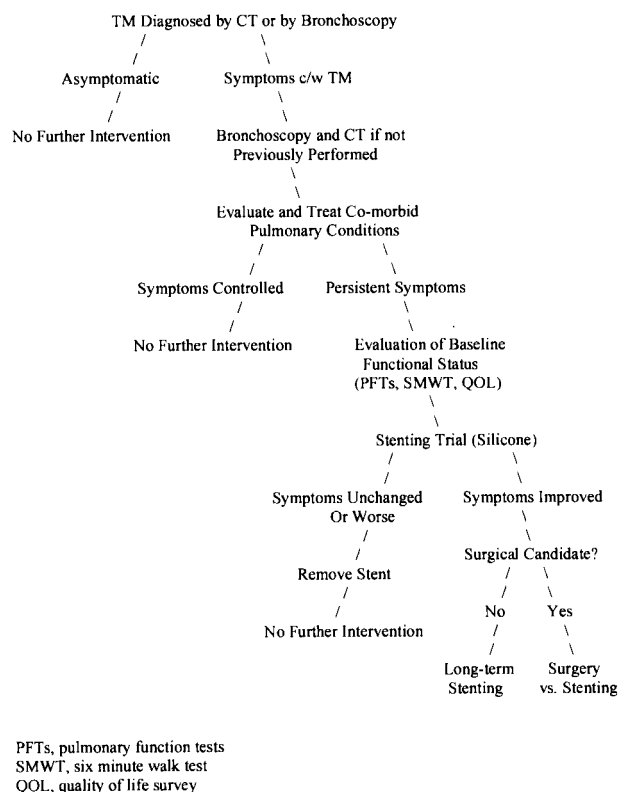


FIGURE 6. Treatment algorithm for adult TM.

ACKNOWLEDGMENT: The authors thank Simon Ashiku, MD (Division of Cardiothoracic Surgery, Beth Israel Deaconess Medical Center, Boston, MA), Carl O'Donnell, ScD, MPH (Division of Pulmonary, Critical Care, and Sleep Medicine, Beth Israel Deaconess Medical Center), and David Feller-Kopman (Division of Pulmonary and Critical Care Medicine, Beth Israel Deaconess Medical Center) for their help in the preparation of this article.

REFERENCES

- Austin J, Ali T. Tracheomalacia and bronchomalacia in children: pathophysiology, assessment, treatment, and anaesthesia management. *Paediatr Anaesth* 2003; 13:3–11
- Wittenborg MH, Gyepes MT, Crocker D. Tracheal dynamics in infants with respiratory distress, stridor, and collapsing trachea. *Radiology* 1967; 88:653–662
- Heinbecker P. A method for the demonstration of calibre changes in the bronchi in normal respiration. *J Clin Invest* 1927; 4:459–469
- Feist JH, Johnson TH, Wilson RJ. Acquired tracheomalacia: etiology and differential diagnosis. *Chest* 1975; 68:340–345
- Nuutinen J. Acquired tracheobronchomalacia. *Eur J Respir Dis* 1982; 63:380–387
- Filler RM, Rossello PJ, Lebowitz RL. Life-threatening anoxic spells caused by tracheal compression after repair of esophageal atresia: correction by surgery. *J Pediatr Surg* 1976; 11:739–748
- Kiely EM, Spitz L, Brereton R. Management of tracheomalacia by aortopexy. *Pediatr Surg Int* 1987; 2:13–15
- Mair EA, Parsons DS. Pediatric tracheobronchomalacia and major airway collapse. *Ann Otol Rhinol Laryngol* 1992; 101:300–309
- Gross RE. Surgical relief for tracheal obstruction from a vascular ring. *N Engl J Med* 1945; 223:586–590
- Wolman IJ. Syndrome of constricting double aortic arch in infancy: report of a case. *J Pediatr* 1939; 14:527–533
- Sprague HB, Erlund CH, Albright F. Clinical aspects of persistent right aortic root. *N Engl J Med* 1933; 209: 679–686
- Gross RE, Neuhauser EBD. Compression of the trachea by an anomalous innominate artery: an operation for its relief. *Am J Dis Child* 1948; 75:570–577
- Evans WA. Congenital obstructions of the respiratory tract: Part I. Tracheal malformation. *AJR Am J Roentgenol* 1949; 62:167–176
- Kirklin JW, Claggett OT. Vascular rings producing respiratory obstruction in infants. *Mayo Clin Proc* 1950; 25: 360–367
- Holinger PH, Johnston KC, Parchet VN, et al. Congenital malformations of the trachea, bronchi, and lung. *Ann Otol Rhinol Laryngol* 1952; 61:1159–1180
- Holinger PH. Clinical aspects of congenital anomalies of the larynx, trachea, bronchi, and oesophagus: the Semon lecture. *J Laryngol Otol* 1961; 75:1–44
- Baxter JD, Dunbar JS. Tracheomalacia. *Ann Otol Rhinol Laryngol* 1963; 72:1013–1023
- Gupta TG, Goldberg SJ, Lewis E, et al. Congenital bronchomalacia. *Am J Dis Child* 1968; 115:88–89
- Masaoka A, Yamakawa Y, Niwa H, et al. Pediatric and adult tracheobronchomalacia. *Eur J Cardiothorac Surg* 1996; 10: 87–92
- Holinger LD. Etiology of stridor in the neonate, infant, and child. *Ann Otol Rhinol Laryngol* 1980; 89:397–400
- Jacobs IN, Wetmore RF, Tom LW, et al. Tracheobronchomalacia in children. *Arch Otolaryngol Head Neck Surg* 1994; 120:154–158
- Masters IB, Chang AB, Patterson L, et al. Series of laryngomalacia, tracheomalacia, and bronchomalacia disorders and their associations with other conditions in children. *Pediatr Pulmonol* 2002; 34:189–195
- Blair GK, Cohen R, Filler RM. Treatment of tracheomalacia: eight years' experience. *J Pediatr Surg* 1986; 21:781–785
- Adler SC, Isaacson G, Balsara RK. Innominate artery compression of the trachea: diagnosis and treatment by anterior suspension: a 25-year experience. *Ann Otol Rhinol Laryngol* 1995; 104:924–927
- Johner CH, Szanto PA. Polychondritis in a newborn presenting as tracheomalacia. *Ann Otol Rhinol Laryngol* 1970; 79:1114–1116
- Cox WL, Shaw RR. Congenital chondromalacia of the trachea. *J Thorac Cardiovasc Surg* 1965; 49:1033–1039
- Morehead JM, Parsons DS. Tracheobronchomalacia in Hunter's syndrome. *Int J Pediatr Otorhinolaryngol* 1993; 26:255–261
- Shapiro J, Strome M, Crocker AC. Airway obstruction and sleep apnea in Hurler and Hunter syndromes. *Ann Otol Rhinol Laryngol* 1985; 94:458–461
- Benjamin B. Tracheomalacia in infants and children. *Ann Otol Rhinol Laryngol* 1984; 93:438–442
- Paston F, Bye M. Tracheomalacia. *Pediatr Rev* 1996; 17:328
- Greenholz SK, Karrer FM, Lilly JR. Contemporary surgery of tracheomalacia. *J Pediatr Surg* 1986; 21:511–514
- Wailoo MP, Emery JL. The trachea in children with tracheo-oesophageal fistula. *Histopathology* 1979; 3: 329–338
- Mustard WT, Bayliss CE, Fearon B, et al. Tracheal compression by the innominate artery in children. *Ann Thorac Surg* 1969; 8:312–319
- Moes CA, Izukawa T, Trusler GA. Innominate artery compression of the trachea. 1975; 101:733–738
- Cohen D. Tracheopexy-aorto-tracheal suspension for severe tracheomalacia. *Aust Paediatr J* 1981; 17:117–121
- Cogbill TH, Moore FA, Accurso FJ, et al. Primary tracheomalacia. *Ann Thorac Surg* 1983; 35:538–541
- Chen H, Chang CH, Perrin E, et al. A lethal, Larsen-like multiple joint dislocation syndrome. *Am J Med Genet* 1982; 13:149–161
- Windsor HM, Shanahan MX, Cherian K, et al. Tracheal injury following prolonged intubation. *Aust N Z J Surg* 1976; 46:18–25
- Duncan S, Eid N. Tracheomalacia and bronchopulmonary dysplasia. *Ann Otol Rhinol Laryngol* 1991; 100:856–858
- Azizkhan RG, Lacey SR, Wood RE. Anterior cricoid suspension and tracheal stomal closure for children with cricoid collapse and peristomal tracheomalacia following tracheostomy. *J Pediatr Surg* 1993; 28:169–171
- Johnston RF, Green RA. Tracheobronchiomegaly: report of five cases and demonstration of familial occurrence. *Am Rev Respir Dis* 1965; 91:35–50
- MacMahon HE, Ruggieri J. Congenital segmental bronchomalacia. *Am J Dis Child* 1969; 118:923–926
- Krivchenia DI, Slepov AK, Zavodii VG, et al. Surgical correction of intrathoracic compression of respiratory airways due to double aortic arch in children. *Klin Khir* 2000; 6:27–30
- Sebening C, Jakob H, Tochtermann U, et al. Vascular tracheobronchial compression syndromes: experience in surgical treatment and literature review. *Thorac Cardiovasc Surg* 2000; 48:164–174
- Snelling CE, Erb IH. Double aortic arch. *Arch Dis Child* 1933; 8:401–408
- Heck HAJ, Moore HV, Lutin WA, et al. Esophageal-aortic erosion associated with double aortic arch and tracheoma-

- lacia: experience with 2 infants. *Tex Heart Inst J* 1993; 20:126–129
- 47 Vasko JS, Ahn C. Surgical management of secondary tracheomalacia. *Ann Thorac Surg* 1968; 6:269–272
 - 48 Ardito JM, Ossoff RH, Tucker GFJ, et al. Innominate artery compression of the trachea in infants with reflex apnea. *Ann Otol Rhinol Laryngol* 1980; 89:401–405
 - 49 Fearon B, Shortreed R. Tracheobronchial compression by congenital cardiovascular anomalies in children: syndrome of apnea. *Ann Otol Rhinol Laryngol* 1963; 72:949–969
 - 50 Rivilla F, Utrilla JG, Alvarez F. Surgical management and follow-up of vascular rings. *Z Kinderchir* 1989; 44:199–202
 - 51 Koopot R, Nikaidoh H, Idriss FS. Surgical management of anomalous left pulmonary artery causing tracheobronchial obstruction: pulmonary artery sling. *J Thorac Cardiovasc Surg* 1975; 69:239–246
 - 52 Potts WJ, Holinger PH, Rosenblum AH. Anomalous left pulmonary artery causing obstruction to right main bronchus: report of a case. *J Am Med Assoc* 1954; 155:1409–1411
 - 53 Dailey ME, O’Laughlin MP, Smith RJ. Airway compression secondary to left atrial enlargement with increased pulmonary artery pressure. *Int J Pediatr Otorhinolaryngol* 1990; 19:33–44
 - 54 Andrews TM, Myers CMI, Gray SP. Abnormalities of the bony thorax causing tracheobronchial compression. *Int J Pediatr Otorhinolaryngol* 1990; 19:139–144
 - 55 Godfrey S. Association between pectus excavatum and segmental bronchomalacia. *J Pediatr* 1980; 96:649–652
 - 56 Shaha AR, Alfonso AE, Jaffe BM. Operative treatment of substernal goiters. *Head Neck Surg* 1989; 11:325–330
 - 57 Geelhoed GW. Tracheomalacia from compressing goiter: management after thyroidectomy. *Surgery* 1988; 104:1100–1108
 - 58 Krivchenia DI, Slepov AK, Chumakova LF. Intrathoracic compression of the respiratory airways by mediastinal teratomas in children. *Lik Sprava* 2001; 4:92–95
 - 59 Krivchenia DI, Slepov AK, Chumakova LF. Intrathoracic compression of the respiratory tracts caused by broncho- and enterogenic mediastinal cysts in children. *Lik Sprava* 1999; 7–8:87–90
 - 60 Krivchenia DI, Slepov AK, Zavodii VG, et al. Surgical treatment of bronchogenic and enterogenic mediastinal cysts complicated by intrathoracic compression of respiratory tracts in children. *Klin Khir* 2001; 1:26–28
 - 61 Engum SA, Grosfeld JL, West KW, et al. Analysis of morbidity and mortality in 227 cases of esophageal atresia and/or tracheoesophageal fistula over two decades. *Arch Surg* 1995; 130:502–508
 - 62 Kimura K, Soper RT, Kao S, et al. Aortosternotomy for tracheomalacia following repair of esophageal atresia: evaluation by cine-CT and technical refinement. *J Pediatr Surg* 1990; 25:769–772
 - 63 Bradham RR, Sealy WC, Young WG. Respiratory distress associated with anomalies of the aortic arch. *Surg Gynecol Obstet* 1968; 126:9–14
 - 64 Mair EA, Parsons DS, Lally KP. Treatment of severe bronchomalacia with expanding endobronchial stents. *Arch Otolaryngol Head Neck Surg* 1990; 116:1087–1090
 - 65 Cohn RC, Kerckmar C, Dearborn D. Safety and efficacy of flexible endoscopy in children with bronchopulmonary dysplasia. *Am J Dis Child* 1988; 142:1225–1228
 - 66 Doull IJM, Mok Q, Tasker RC. Tracheobronchomalacia in preterm infants with chronic lung disease. *Arch Dis Child* 1997; 76:F203–F205
 - 67 Miller RW, Woo P, Kellman RK, et al. Tracheobronchial abnormalities in infants with bronchopulmonary dysplasia. *J Pediatr* 1987; 111:779–782
 - 68 Greenholz SK, Hall RJ, Lilly JR, et al. Surgical implications of bronchopulmonary dysplasia. *J Pediatr Surg* 1987; 22:1132–1136
 - 69 Lindahl H, Rintala R, Malinen L, et al. Bronchoscopy during the first month of life. *J Pediatr Surg* 1992; 27:548–550
 - 70 Downing GJ, Kilbride HW. Evaluation of airway complications in high-risk preterm infants: application of flexible fiberoptic airway endoscopy. *Pediatrics* 1995; 95:567–572
 - 71 Malone PS, Kiely EM. Role of aortopexy in the management of primary tracheomalacia and tracheobronchomalacia. *Arch Dis Child* 1990; 65:438–440
 - 72 Bibi H, Khvolis E, Shoseyov D, et al. The prevalence of gastroesophageal reflux in children with tracheomalacia and laryngomalacia. *Chest* 2001; 119:409–413
 - 73 Spitz L, Kiely E, Brereton RJ. Esophageal atresia: five year experience with 148 cases. *J Pediatr Surg* 1987; 22:103–108
 - 74 Vinograd I, Filler RM, Bahoric A. Long-term functional results of prosthetic airway splinting in tracheomalacia and bronchomalacia. *J Pediatr Surg* 1987; 22:38–41
 - 75 Weber TR, Keller MS, Fiore A. Aortic suspension (aortopexy) for severe tracheomalacia in infants and children. *Am J Surg* 2002; 184:573–577
 - 76 Filler RM, Messineo A, Vinograd I. Severe tracheomalacia associated with esophageal atresia: results of surgical treatment. *J Pediatr Surg* 1992; 27:1136–1140
 - 77 Benjamin B, Cohen D, Glasson M. Tracheomalacia in association with congenital tracheo-esophageal fistula. *Surgery* 1976; 79:504–508
 - 78 Denney JCR. Bronchomalacia in the neonate. *Ann Otol Rhinol Laryngol* 1985; 94:466–469
 - 79 Wheeler WB, Maguire EL, Kurachek SC, et al. Chronic respiratory failure of infancy and childhood: clinical outcomes based on underlying etiology. *Pediatr Pulmonol* 1994; 17:1–5
 - 80 Wailoo M, Emery JL. The trachea in children with respiratory diseases including children presenting as cot deaths. *Arch Dis Child* 1980; 55:199–203
 - 81 Wailoo M, Emery JL. Structure of the membranous trachea in children. *Acta Anat (Basel)* 1980; 106:254–261
 - 82 Benjamin B. Endoscopy in esophageal atresia and tracheo-esophageal fistula. *Ann Otol Rhinol Laryngol* 1981; 90:376–382
 - 83 Callahan CW. Primary tracheomalacia and gastroesophageal reflux in infants with cough. *Clin Pediatr* 1998; 37:725–731
 - 84 Agosti E, DeFilippi G, Fior R, et al. Generalized familial bronchomalacia. *Acta Paediatr Scand* 1974; 63:616–618
 - 85 Picot C, Monnet P, Bethenod M, et al. Tracheomalacia in infants. *Arch Fr Pediatr* 1969; 26:493–506
 - 86 Sotomayor JL, Godinez RI, Borden S, et al. Large-airway collapse due to acquired tracheobronchomalacia in infancy. *Am J Dis Child* 1986; 140:367–371
 - 87 Sommer D, Forte V. Advances in the management of major airway collapse: the use of airway stents. *Otolaryngol Clin North Am* 2000; 33:163–177
 - 88 Slany E, Holzki J, Holschneider AM, et al. Tracheal instability in tracheo-esophageal abnormalities. *Z Kinderchir* 1990; 45:78–85
 - 89 Levin SJ, Adler P, Scherer RA. Collapsible trachea (tracheomalacia): a non-allergic cause of wheezing in infancy. *Ann Allergy* 1964; 22:20–25
 - 90 Salzberg AM, Ehrlich FE. Congenital malformations of the lower respiratory tract. 3rd ed. Philadelphia, PA: Saunders, 1977
 - 91 Griffiths H, Doull I, Williams RG, et al. Tracheomalacia and

- breath holding: a case report. *Arch Dis Child* 2000; 83: 340–341
- 92 Lynch JI. Bronchomalacia in children: considerations governing medical vs surgical treatment. *Clin Pediatr* 1970; 9: 279–282
 - 93 Emery JL, Haddadin AJ. Squamous epithelium in the respiratory tract of children with tracheo-esophageal fistula, and “retention lung.” *Arch Dis Child* 1971; 46:884
 - 94 Schwartz MZ, Filler RM. Tracheal compression as a cause of apnea following repair of tracheoesophageal fistula: treatment by aortopexy. *J Pediatr Surg* 1980; 15:842–848
 - 95 Okuda Y, Sato H, Kitajima T, et al. Airway obstruction during general anaesthesia in a child with congenital tracheomalacia. *Eur J Anaesthesiol* 2000; 17:642–644
 - 96 Oh AY, Kim YH, Kim BK, et al. Unexpected tracheomalacia in Marfan syndrome during general anesthesia for correction of scoliosis. *Anesth Analg* 2002; 95:331–332
 - 97 Asai T, Shingu K. Airway obstruction in a child with asymptomatic tracheobronchomalacia. *Can J Anaesth* 2001; 48:684–687
 - 98 Ahel V, Banac S, Rozmanic V, et al. Aortopexy and bronchopexy for the management of severe tracheomalacia and bronchomalacia. *Pediatr Int* 2003; 45:104–106
 - 99 Davies MR, Cywes S. The flaccid trachea and tracheoesophageal congenital anomalies. *J Pediatr Surg* 1978; 13:363–367
 - 100 Filler RM. Tracheomalacia. In: Fallis J, Filler R, Lemoine G, eds. *Pediatric thoracic surgery: an international series*. New York, NY: Elsevier, 1991; 163–169
 - 101 Davis S, Jones M, Kisling J, et al. Effect of continuous positive airway pressure on forced expiratory flows in infants with tracheomalacia. *Am J Respir Crit Care Med* 1998; 158:148–152
 - 102 Abramson AL, Goldstein MN, Stenzler A, et al. The use of tidal breathing flow volume loop in laryngotracheal disease of neonates and infants. *Laryngoscope* 1982; 92:922–926
 - 103 Kahn A, Baran D, Spehl M, et al. Congenital stridor in infancy: clinical lessons derived from a survey of 31 instances. *Clin Pediatr* 1977; 16:19–26
 - 104 Jasin ME, Osguthorpe JD. The radiographic evaluation of infants with stridor. *Otolaryngol Head Neck Surg* 1982; 90:736–739
 - 105 Walner DL, Ouanounou S, Donnelly LF, et al. Utility of radiographs in the evaluation of pediatric upper airway obstruction. *Ann Otol Rhinol Laryngol* 1999; 108:378–383
 - 106 Frey EE, Smith WL, Grandgeorge S, et al. Chronic airway obstruction in children: evaluation with cine-CT. *AJR Am J Roentgenol* 1987; 148:347–352
 - 107 Boiselle PM, Ernst A. Recent advances in central airway imaging. *Chest* 2002; 121:1651–1660
 - 108 Donnelly LF, Frush DP. Pediatric multidetector body CT. *Radiol Clin North Am* 2003; 41:637–655
 - 109 Boiselle PM, Dipolito G, Copeland J, et al. Multiplanar and 3D imaging of the central airways: comparison of image quality and radiation dose of single-detector row CT and multi-detector row CT at differing tube currents in dogs. *Radiology* 2003; 228:107–111
 - 110 Konen E, Katz M, Rozenman J, et al. Virtual bronchoscopy in children: early clinical experience. *AJR Am J Roentgenol* 1998; 171:1699–1702
 - 111 Faust RA, Remley KB, Rimell FL. Real-time, cine magnetic resonance imaging for evaluation of the pediatric airway. *Laryngoscope* 2001; 111:2187–2190
 - 112 Faust RA, Rimell FL, Remley KB. Cine magnetic resonance imaging for evaluation of focal tracheomalacia: innominate artery compression syndrome. *Int J Pediatr Otorhinolaryngol* 2002; 65:27–33
 - 113 Rimell FL, Shapiro AM, Meza MP, et al. Magnetic resonance imaging of the pediatric airway. *Arch Otolaryngol Head Neck Surg* 1997; 123:999–1003
 - 114 Page BA, Klein EFJ. Tracheal stent as an aid in weaning from mechanical ventilation in tracheomalacia. *Anesthesiology* 1977; 47:300–301
 - 115 Shapiro RS, Martin WM. Long custom-made plastic tracheostomy tube in severe tracheomalacia. *Laryngoscope* 1981; 91:355–362
 - 116 Levine PA, Sasaki CT, Kirchner JA. The long tracheostomy tube: alternative management of distal tracheal stenosis. *Arch Otolaryngol* 1978; 104:108–110
 - 117 Galvis AG, Heller RM, Haller JAJ. Custom-made tracheostomy tube to relieve lower tracheal obstruction in infants and young children. *Pediatrics* 1977; 59:40–44
 - 118 Altman KW, Wetmore RF, March RR. Congenital airway abnormalities in patients requiring hospitalization. *Arch Otolaryngol Head Neck Surg* 1999; 125:525–528
 - 119 Altman KW, Wetmore RF, March RR. Congenital airway abnormalities requiring tracheotomy: a profile of 56 patients and their diagnoses over a 9 year period. *Int J Pediatr Otorhinolaryngol* 1997; 41:199–206
 - 120 Duncan BW, Howell LJ, DeLorimier AA. Tracheostomy in children with emphasis on home care. *J Pediatr Surg* 1992; 27:432–435
 - 121 Kanter RK, Pollack MM, Wright WW, et al. Treatment of severe tracheobronchomalacia with continuous positive airway pressure (CPAP). *Anesthesiology* 1982; 57:54–56
 - 122 Wiseman NE, Duncan PG, Cameron CB. Management of tracheobronchomalacia with continuous positive airway pressure. *J Pediatr Surg* 1985; 20:489–493
 - 123 Reiterer F, Eber E, Zach MS, et al. Management of severe congenital tracheobronchomalacia by continuous positive airway pressure and tidal breathing flow-volume loop analysis. *Pediatr Pulmonol* 1994; 17:401–403
 - 124 Pizer BL, Freeland AP, Wilkinson AR. Prolonged positive airway pressure for severe neonatal tracheobronchomalacia. *Arch Dis Child* 1986; 61:908–909
 - 125 Miller RW, Pollack MM, Murphy TM, et al. Effectiveness of continuous positive airway pressure in the treatment of bronchomalacia in infants: a bronchoscopic documentation. *Crit Care Med* 1986; 14:125–127
 - 126 Ferguson GT, Benoist J. Nasal continuous positive airway pressure in the treatment of tracheobronchomalacia. *Am Rev Respir Dis* 1993; 147:457–461
 - 127 Neijens HJ, Kerrebijn KF, Smalhout B. Successful treatment with CPAP of two infants with bronchomalacia. *Acta Paediatr Scand* 1978; 67:293–296
 - 128 Panitch HB, Allen JL, Alpert BE, et al. Effects of CPAP on lung mechanics in infants with acquired tracheobronchomalacia. *Am J Respir Crit Care Med* 1994; 150:1341–1346
 - 129 Kulkarni PB, Dorand RD, Payne JH. Severe tracheomalacia in a newborn requiring assisted ventilation. a case report. *Ala J Med Sci* 1983; 20:19–20
 - 130 Kamata S, Usui N, Sawai T, et al. Pexis of the great vessels for patients with tracheobronchomalacia in infancy. *J Pediatr Surg* 2000; 35:454–457
 - 131 Johnston MR, Loeber N, Hillyer P, et al. External stent of repair of secondary tracheomalacia. *Ann Thorac Surg* 1980; 30:291–296
 - 132 Messineo A, Filler RM. Tracheomalacia. *Semin Pediatr Surg* 3:253–258, 1994
 - 133 Morabito A, MacKinnon E, Alizai N, et al. The anterior mediastinal approach for management of tracheomalacia. *J Pediatr Surg* 2000; 35:1456–1458
 - 134 Abdel-Rahman U, Ahrens P, Fieguth HG, et al. Surgical treatment of tracheomalacia by bronchoscopic monitored

- aortopexy in infants and children. *Ann Thorac Surg* 2002; 74:315–319
- 135 Brawn WJ, Huddart SN. Tracheo-aortopexy via midline sternotomy in tracheomalacia. *J Pediatr Surg* 1991; 26: 660–662
- 136 Bullard KM, Scott Adzick N, Harrison MR. A mediastinal window approach to aortopexy. *J Pediatr Surg* 1997; 32: 680–681
- 137 Delgado MD, Matute JA, Jimenez MA, et al. The treatment of the tracheobronchomalacia in pediatric age. *Cir Pediatr* 1997; 10:65–69
- 138 Schaarschmidt K, Kolberg-Schwerdt A, Pietsch L, et al. Thorascopic aortopercardiosternopexy for severe tracheomalacia in toddlers. *J Pediatr Surg* 2002; 37:1476–1478
- 139 Hawkins JA, Bailey WW, Clark SM. Innominate artery compression of the trachea: treatment by reimplantation of the innominate artery. *J Thorac Cardiovasc Surg* 1992; 103:678–682
- 140 Backer CL, Holinger LD, Mavroudis C. Innominate artery compression: division and reimplantation versus suspension. *J Thorac Cardiovasc Surg* 1992; 103:817–820
- 141 DeLeon SY, Quinones JA, Pifarre R. Aortoinnominate pexy versus innominate artery reimplantation for displaced innominate artery. *J Thorac Cardiovasc Surg* 1994; 107: 947–948
- 142 Yamaguchi S, Takanishi T, Matsumoto T, et al. Use of a laryngeal mask airway for anesthesia in a patient with bronchomalacia. *Masui* 1996; 45:348–351
- 143 Conroy PT, Bennett NR. Management of tracheomalacia in association with congenital tracheo-oesophageal fistula. *Br J Anaesth* 1987; 59
- 144 Cacciaguerra S, Bianchi A. Tracheal ring-graft reinforcement in lieu of tracheostomy for tracheomalacia. *Pediatr Surg Int* 1998; 13:556–559
- 145 Filler RM, Buck JR, Bahoric A, et al. Treatment of segmental tracheomalacia and bronchomalacia by implantation of an airway splint. *J Pediatr Surg* 1982; 17:597–603
- 146 Murphy JP, Filler RM, Muraji T, et al. Effect of prosthetic airway splint on the growing trachea. *J Pediatr Surg* 1983; 18:872–878
- 147 Vaishnav A, MacKinnon AE. New cervical approach for tracheopexy. *Br J Surg* 1986; 73:441–442
- 148 Meyer R. Tracheopexy in tracheomalacia. *Pract Otorhinolaryngol (Basel)* 1968; 30:161–172
- 149 Grillo HC, Zannini P. Management of obstructive tracheal disease in children. *J Pediatr Surg* 1984; 19:414–416
- 150 Meyer R. New concepts in laryngotracheal reconstruction. *Trans Am Acad Ophthalmol Otolaryngol* 1972; 76:758–765
- 151 Montgomery WW. T-tube tracheal stent. *Arch Otolaryngol* 1965; 82:320–321
- 152 Tazuke Y, Kawahara H, Yagi M, et al. Use of a Palmaz stent for tracheomalacia: case report of an infant with esophageal atresia. *J Pediatr Surg* 1999; 34:1291–1293
- 153 Filler RM, Forte V, Chait P. Tracheobronchial stenting for the treatment of airway obstruction. *J Pediatr Surg* 1998; 33:304–311
- 154 Furman RH, Backer CL, Dunham ME, et al. The use of balloon-expandable metallic stents in the treatment of pediatric tracheomalacia and bronchomalacia. *Arch Otolaryngol Head Neck Surg* 1999; 125:203–207
- 155 Sewall GK, Warner T, Conner NP, et al. Comparison of resorbable poly-L-lactic acid-polyglycolic acid and internal Palmaz stents for the surgical correction of severe tracheomalacia. *Ann Otol Rhinol Laryngol* 2003; 112:515–521
- 156 Czychlarz ER. Ueber ein pulsionsdivertikel der trachea mit bemerkungen uber das verhalten der elastischen fasern an normalen tracheen und bronchein. *Zentralbl Allg Pathol* 1897; 18:721–728
- 157 Mounier-Kuhn P. Dilatation de la trachee: constatations radiographiques et bronchoscopiques. *Lyons Medical* 1932; 150:106–109
- 158 Lemoine JM. Dyspnees et retractions de la trachee et des grosses bronches. *Semin Hop Paris* 1949; 25:3984–3987
- 159 Pohl R. Universal conditions of malacia at the level of the tracheobronchial system (universelle erweichungszustande am tracheobronchialsystem (tracheo-bronchopthia malacica)). *Fortschr Geb Rontgenstr Nuklearmed* 1951; 74:40–43
- 160 Herzog H, Nissen R. Relaxation and expiratory invagination of the membranous portion of the intrathoracic trachea and the main bronchi as cause of asphyxial attacks in bronchial asthma and the chronic asthmoid bronchitis of pulmonary emphysema. *Schweiz Med Wochenschr* 1954; 84:217–221
- 161 Ferraris A. Essential diffuse tracheobronchomalacia, clinical and endoscopic symptomatology. *Rass Fisiopatol Clin Ter* 1954; 26:430–435
- 162 Greene R, Lechner GL. “Saber-sheath” trachea: a clinical and functional study of marked coronal narrowing of the intrathoracic trachea. *Radiology* 1975; 115:265–268
- 163 Funatsu T, Taki T, Matsubara Y, et al. Diagnosis and treatment of tracheobronchomalacia with asthmatic attack. In: Nakhosteen J, Maassen W, eds. *Bronchology: research, diagnostic and therapeutic aspects*. The Hague, the Netherlands: Nijhoff, 1981; 237–239
- 164 Imaizumi H, Kaneko M, Mori K, et al. Reversible acquired tracheobronchomalacia of a combined crescent type and saber-sheath type. *J Emerg Med* 1995; 13:43–49
- 165 Schwartz M, Rossoff L. Tracheobronchomegaly. *Chest* 1994; 106:1589–1590
- 166 Gay S, Dee P. Tracheobronchomegaly: the Mounier-Kuhn syndrome. *Br J Radiol* 1984; 57:640–644
- 167 Shin MS, Jackson RM, Ho KJ. Tracheobronchomegaly (Mounier-Kuhn syndrome): CT diagnosis. *AJR Am J Roentgenol* 1988; 150:777–779
- 168 Katz I, Levine M, Herman P. Tracheobronchiomegaly: the Mounier-Kuhn syndrome. *Am J Roentgenol Radium Ther Nucl Med* 1962; 88:1084–1094
- 169 Bateson EM, Woo-Ming M. Tracheobronchomegaly. *Clin Radiol* 1973; 24:354–358
- 170 Benesch M, Eber E, Pflieger A, et al. Recurrent lower respiratory tract infections in a 14-year-old boy with tracheobronchomegaly (Mounier-Kuhn syndrome). *Pediatr Pulmonol* 2000; 29:476–479
- 171 Himalstein MR, Gallagher JC. Tracheobronchiomegaly. *Ann Otol Rhinol Laryngol* 1973; 82:223–227
- 172 Susanto I, Peters JI, Levine SM, et al. Use of balloon-expandable metallic stents in the management of bronchial stenosis and bronchomalacia after lung transplantation. *Chest* 1998; 114:1330–1335
- 173 Gotway MB, Golden JA, LaBerge JM, et al. Benign tracheobronchial stenoses: changes in short-term and long-term pulmonary function testing after expandable metallic stent placement. *J Comput Assist Tomogr* 2002; 26:564–572
- 174 Bolot G, Poupard M, Pignat JC, et al. Self-expanding metal stents for the management of bronchial stenosis and bronchomalacia after lung transplantation. *Laryngoscope* 1998; 108:1230–1233
- 175 Jokinen K, Palva T, Nuutinen J. Chronic bronchitis: a bronchologic evaluation. *ORL J Otorhinolaryngol Relat Spec* 1976; 38:178–186
- 176 Jokinen K, Palva T, Sutinen S, et al. Acquired tracheobronchomalacia. *Ann Clin Res* 1977; 9:52–57
- 177 Rahim AAA, Ahmed ME, Hassan MA. Respiratory complications after thyroidectomy and the need for tracheostomy

- in patients with large goiter. *Br J Surg* 1999; 86:88–90
- 178 Doherty MJ, Spence DP, Graham D, et al. A vibrating trachea. *Thorax* 1998; 53:230–231
 - 179 Adliff M, Ngato D, Keshavjee S, et al. Treatment of diffuse tracheomalacia secondary to relapsing polychondritis with continuous positive airway pressure. *Chest* 1997; 112:1701–1704
 - 180 McAdam LP, O'Hanlon MA, Bluestone R, et al. Relapsing polychondritis: prospective study of 23 patients and a review of the literature. *Medicine* 1976; 55:193–215
 - 181 Eng J, Sabanathan S. Airway complications in relapsing polychondritis. *Ann Thorac Surg* 1991; 51:686–692
 - 182 Neilly JB, Winter JH, Stevenson RD. Progressive tracheobronchial polychondritis: need for early diagnosis. *Thorax* 1985; 40:78–79
 - 183 Grathwohl KW, Afifi AY, Dillard TA, et al. Vascular rings of the thoracic aorta in adults. *Am Surg* 1999; 65:1077–1083
 - 184 Campbell AH, Faulks LW. Expiratory air-flow pattern in tracheobronchial collapse. *Am Rev Respir Dis* 1965; 92:781–791
 - 185 Kiener M, Koblet H, Wyss F. Pathology of stenosed bronchial collapse with pulmonary emphysema. *Schweiz Med Wochenschr* 1957; 87:660–663
 - 186 Herzog H. Expiratory stenosis of the trachea and great bronchi by loosening of the membranous portion; plastic chip repair. *Thoraxchirurgie* 1958; 5:281–319
 - 187 Ikeda S, Hanawa T, Konishi T, et al. Diagnosis, incidence, clinicopathology and surgical treatment of acquired tracheobronchomalacia. *Nihon Kyobu Shikkan Gakkai Zasshi* 1992; 30:1028–1035
 - 188 Nuutinen J, Leinonen A. Acquired tracheobronchomalacia: a cineradiographic study with bronchological correlations. *Ann Clin Res* 1977; 9:365–368
 - 189 Nuutinen J. Acquired tracheobronchomalacia: a clinical study with bronchological correlations. *Ann Clin Res* 1977; 9:350–355
 - 190 Nuutinen J. Acquired tracheobronchomalacia: a bronchological follow-up study. *Ann Clin Res* 1977; 9:359–364
 - 191 Johnson TH, Mikita JJ, Wilson RJ, et al. Acquired tracheomalacia. *Radiology* 1973; 109:576–580
 - 192 Demajumdar R, Rajesh PB. Have we got the full picture? *J Laryngol Otol* 1998; 112:788–789
 - 193 Koziej M, Gorecka D. Cough-syncope syndrome in tracheobronchomalacia. *Pneumonol Alergol Pol* 1992; 60:89–91
 - 194 Katoh H, Saitoh S, Takiguchi M, et al. A case of tracheomalacia during isoflurane anesthesia. *Anesth Analg* 1995; 80:1051–1053
 - 195 Collard P, Freitag L, Reynaert MS, et al. Respiratory failure due to tracheobronchomalacia. *Thorax* 1996; 51:224–226
 - 196 Gilkeson RC, Ciancibello LM, Hejal RB, et al. Tracheobronchomalacia: dynamic airway evaluation with multidetector CT. *AJR Am J Roentgenol* 2001; 176:205–210
 - 197 Aquino SL, Shepard JA, Gimms LC, et al. Acquired tracheomalacia: detection by expiratory CT scan. *J Comput Assist Tomogr* 2001; 25:394–399
 - 198 Stern EJ, Graham CM, Webb WR, et al. Normal trachea during forced expiration: dynamic CT measurements. *Radiology* 1993; 187:27–31
 - 199 Hein E, Rogalla P, Hentschel C, et al. Dynamic and quantitative assessment of tracheomalacia by electron beam tomography: correlation with clinical symptoms and bronchoscopy. *J Comput Assist Tomogr* 2000; 24:247–252
 - 200 Heussel CP, Hafner B, Lill J, et al. Paired inspiratory/ expiratory spiral CT and continuous respiration cine CT in the diagnosis of tracheal instability. *Eur Radiol* 2001; 11:982–989
 - 201 Kao SC, Smith WL, Sato Y, et al. Ultrafast CT of laryngeal and tracheobronchial obstruction in symptomatic postoperative infants with esophageal atresia and tracheoesophageal fistula. *AJR Am J Roentgenol* 1990; 154:345–350
 - 202 Brasch RC, Gould RG, Gooding CA, et al. Upper airway obstruction in infants and children: evaluation with ultrafast CT. *Radiology* 1987; 165:459–466
 - 203 Zhang J, Hasegawa I, Feller-Kopman D, et al. Dynamic expiratory volumetric CT imaging of the central airways: comparison of standard-dose and low-dose techniques. *Acad Radiol* 2003; 10:719–724
 - 204 Boisselle PM, Feller-Kopman D, Ashiku S, et al. Tracheobronchomalacia: evolving role of dynamic multislice helical CT. *Radiol Clin North Am* 2003; 41:627–636
 - 205 Zhang J, Hasegawa I, Hatabu H, et al. Frequency and severity of air trapping at dynamic expiratory CT in patients with tracheobronchomalacia. *AJR Am J Roentgenol* 2004; 182:81–85
 - 206 Suto Y, Tanabe Y. Evaluation of tracheal collapsibility in patients with tracheomalacia using dynamic MR imaging during coughing. *AJR Am J Roentgenol* 1998; 171:393–394
 - 207 Shepard JWJ, Stanson AW, Sheedy PF, et al. Fast-CT evaluation of the upper airway during wakefulness in patients with obstructive sleep apnea. *Prog Clin Biol Res* 1990; 345:273–279
 - 208 Burke AJ, Vining DJ, McGuirt WFJ, et al. Evaluation of airway obstruction using virtual endoscopy. *Laryngoscope* 2000; 110:23–29
 - 209 Wright CD. Tracheomalacia. *Chest Surg Clin N Am* 2003; 13:349–357
 - 210 Gandevia B. The spirogram of gross expiratory tracheobronchial collapse in emphysema. *Q J Med* 1963; 32:23–31
 - 211 Koblet H, Wyss F. Clinical and functional picture of genuine bronchial collapse with lung emphysema. *Helv Med Acta* 1956; 23:553–560
 - 212 Vincken W, Cosio MG. Flow oscillations on the flow-volume loop: a nonspecific indicator of upper airway dysfunction. *Bull Eur Physiopathol Respir* 1985; 21:559–567
 - 213 Garcia-Pachon E. Tracheobronchomalacia: a cause of flow oscillations on the flow-volume loop. *Chest* 2000; 118:1519
 - 214 Vincken W, Cosio M. Flow oscillations on the flow-volume loop: clinical and physiological implications. *Eur Respir J* 1989; 2:543–549
 - 215 Nissen R. Tracheoplastik zur Beseitigung der Erschlaffung des membranösen Teils der intrathorakalen Lufttröhre [abstract]. *Schweiz Med Wochenschr* 1954; 84:219
 - 216 Herzog H, Keller R, Allgower M. Special methods of diagnosing and treating obstructive disease of the central airways. *Chest* 1971; 60:49–67
 - 217 Halttunen P. EDH-adhesive plastic support in the surgical treatment of tracheobronchial collapse: an experimental study and a report on clinical cases. *Acta Chir Scand Suppl* 1973; 440:3–34
 - 218 Amedee RG, Mann WJ, Lyons GD. Tracheomalacia repair using ceramic rings. *Otolaryngol Head Neck Surg* 1992; 106:270–274
 - 219 Hanawa T, Ikeda S, Funatsu T, et al. Development of a new surgical procedure for repairing tracheobronchomalacia. *J Thorac Cardiovasc Surg* 1990; 100:587–594
 - 220 Grillo HC. Tracheal replacement: a critical review. *Ann Thorac Surg* 2002; 73:1995–2004
 - 221 Bollinger CT, Mathur PN, Beamis JF, et al. ERS/ATS statement on interventional pulmonology. *Eur Respir J* 2002; 19:356–373
 - 222 Clarke DB. Palliative intubation of the trachea and main bronchi. *J Thorac Cardiovasc Surg* 1980; 80:736–741
 - 223 Orłowski TM. Palliative intubation of the tracheobronchial tree. *J Thorac Cardiovasc Surg* 1987; 94:343–348

- 224 Casiano RR, Numa WA, Nurko YJ. Efficacy of transoral intraluminal Wallstents for tracheal stenosis and tracheomalacia. *Laryngoscope* 2000; 110:1607–1612
- 225 Dasgupta A, Dolmatch BL, Abi-Saleh WJ, et al. Self-expandable metallic airway stent insertion employing flexible bronchoscopy: preliminary results. *Chest* 1998; 114:106–109
- 226 Hramiec JE, Haasler GB. Tracheal wire stent complications in malacia: implications of position and design. *Ann Thorac Surg* 1997; 63:209–213
- 227 Spinelli P, Meroni E, Cerrai FG. Self-expanding tracheobronchial stents using flexible bronchoscopy: preliminary clinical experience. *Surg Endosc* 1994; 8:411–413
- 228 de Souza AC, Keal R, Hudson NM, et al. Use of expandable wire stents for malignant airway obstruction. *Ann Thorac Surg* 1994; 57:1573–1577
- 229 George PJ, Irving JD, Khaghani A, et al. Role of the Gianturco expandable metal stent in the management of tracheobronchial obstruction. *Cardiovasc Intervent Radiol* 1992; 15:375–381
- 230 Nesbitt JC, Carrasco H. Expandable stents. *Chest Surg Clin N Am* 1996; 6:305–328
- 231 Vergnon JM, Costes F, Bayon MC, et al. Efficacy of tracheal and bronchial stent placement on respiratory functional tests. *Chest* 1995; 107:741–746
- 232 Zannini P, Melloni G, Chiesa G, et al. Self-expanding stents in the treatment of tracheobronchial obstruction. *Chest* 1994; 106:86–90
- 233 Shah R, Sabanathan S, Mearns AJ, et al. Self-expanding tracheobronchial stents in the management of major airway problems. *J Cardiovasc Surg (Torino)* 1995; 36:343–348
- 234 Beer M, Wittenberg G, Sandstede J, et al. Treatment of inoperable tracheobronchial obstructive lesions with the Palmaz stent. *Cardiovasc Intervent Radiol* 1999; 22:109–113
- 235 Nashef SA, Dromer C, Velly JF, et al. Expanding wire stents in benign tracheobronchial disease: indications and complications. *Ann Thorac Surg* 1992; 54:937–940
- 236 Rousseau H, Dahan M, Lauque D, et al. Self-expandable prostheses in the tracheobronchial tree. *Radiology* 1993; 188:199–203
- 237 Muller C, Dienemann H, Hoffmann H, et al. Expandable metal mesh stents for treatment of tracheal stenoses and tracheomalacia. *Zentralbl Chir* 1993; 118:543–548
- 238 Higgins R, McNeil K, Dennis C, et al. Airway stenoses after lung transplantation: management with expanding metal stents. *J Heart Lung Transplant* 1994; 13:774–778
- 239 Eisner MD, Gordon RL, Webb WR, et al. Pulmonary function improves after expandable metal stent placement for benign airway obstruction. *Chest* 1999; 115:1006–1011
- 240 Gelb AF, Zamel N, Colchen A, et al. Physiologic studies of tracheobronchial stents in airway obstruction. *Am Rev Respir Dis* 1992; 146:1088–1090
- 241 Kshetry VR, Kroshus TJ, Hertz MI, et al. Early and late airway complications after lung transplantation: incidence and management. *Ann Thorac Surg* 1997; 63:1576–1583
- 242 O'Donnell CR, Feller-Kopman D, Ernst A, et al. Pressure-flow relationships and airway dynamics in tracheobronchial malacia [abstract]. *Am J Respir Crit Care Med* 2003; 167:A576
- 243 Ross DJ, Belman MJ, Mohsenifar Z, et al. Obstructive flow-volume loop contours after single lung transplantation. *J Heart Lung Transplant* 1994; 13:508–513

**Tracheomalacia and Tracheobronchomalacia in Children and Adults: An
In-depth Review**

Kelly A. Carden, Philip M. Boiselle, David A. Waltz and Armin Ernst

Chest 2005;127;984-1005

DOI: 10.1378/chest.127.3.984

This information is current as of July 26, 2005

Updated Information & Services	Updated information and services, including high-resolution figures, can be found at: http://www.chestjournal.org/cgi/content/full/127/3/984
References	This article cites 239 articles, 55 of which you can access for free at: http://www.chestjournal.org/cgi/content/full/127/3/984#BIBL
Permissions & Licensing	Information about reproducing this article in parts (figures, tables) or in its entirety can be found online at: http://www.chestjournal.org/misc/reprints.shtml
Reprints	Information about ordering reprints can be found online: http://www.chestjournal.org/misc/reprints.shtml
Email alerting service	Receive free email alerts when new articles cite this article sign up in the box at the top right corner of the online article.
Images in PowerPoint format	Figures that appear in CHEST articles can be downloaded for teaching purposes in PowerPoint slide format. See any online article figure for directions.

A M E R I C A N C O L L E G E O F



P H Y S I C I A N S