

# Cholangiocarcinoma

Shahid A Khan, Howard C Thomas, Brian R Davidson, Simon D Taylor-Robinson

Cholangiocarcinoma is a devastating malignancy that presents late, is notoriously difficult to diagnose, and is associated with a high mortality. The incidence of intrahepatic cholangiocarcinoma is increasing worldwide. The cause for this rise is unclear, although it could be related to an interplay between predisposing genetic factors and environmental triggers. MRI and CT with endoscopic ultrasound and PET provide useful diagnostic information in certain patients. Surgical resection is the only chance for cure, with results depending on careful technique and patient selection. Data suggest that liver transplantation could offer long-term survival in selected patients when combined with neoadjuvant chemoradiotherapy. Chemotherapy and radiotherapy have been ineffective for patients with inoperable tumours. For most of these patients biliary drainage is the mainstay of palliation. However, controversy exists over the type and positioning of biliary stents. Photodynamic treatment is a new palliative technique that might improve quality of life.

Cholangiocarcinoma was first reported by Durand-Fardel in 1840.<sup>1</sup> The tumour arises from the ductular epithelium of the biliary tree, either within the liver (intrahepatic cholangiocarcinoma) or more commonly from the extrahepatic bile ducts (extrahepatic cholangiocarcinoma). The disease is notoriously difficult to diagnose and is usually fatal because of its late clinical presentation and the lack of effective non-surgical therapeutic modalities.<sup>2</sup> Most patients have unresectable disease at presentation and die within 12 months from the effects of cancer cachexia and a subsequent rapid decline in performance status. Liver failure and recurrent sepsis, secondary to biliary obstruction, can also contribute to the high mortality.<sup>3</sup> Overall survival rate, including resected patients, is poor, with less than 5% of patients surviving to 5 years, a rate which has not changed significantly over the past 30 years.<sup>4</sup> Although cholangiocarcinoma is a relatively rare tumour, interest in this disease is rising as incidence and mortality rates for intrahepatic tumours increase markedly worldwide.<sup>5–8</sup>

This Seminar reviews the epidemiology, aetiology, and diagnostic strategies for cholangiocarcinoma. We also assess therapeutic options, including potentially curative surgical resection and transplantation, as well as palliative options, such as photodynamic therapy and the role of stents.

## Classification

More than 90% of cholangiocarcinomas are adenocarcinomas.<sup>9</sup> 60–70% arise at the bifurcation of the hepatic ducts (Klatskin tumours)<sup>10</sup> and 20–30% in the distal common bile duct. 5–10% of cholangiocarcinomas are peripheral, arising within intrahepatic ducts of the liver parenchyma itself.<sup>10</sup> Intrahepatic cholangiocarcinomas originate in the small bile ducts and tend to be grouped, by international classification of disease (ICD) codes, with hepatocellular carcinoma as primary liver tumours.<sup>5,11</sup> In an analysis of database registries of the Surveillance Epidemiology and End Results (SEER) 1975–99, 92% of Klatskin tumours were classified as intrahepatic.<sup>4</sup> Cholangio-

carcinomas can thus be classified anatomically into intrahepatic (including hilar) or extrahepatic tumours; or alternatively, in the case of intrahepatic tumours, by growth characteristics, by which tumours are identified as mass-forming, periductal-infiltrating, or intraductal growing types.<sup>12</sup>

## Epidemiology

Worldwide, cholangiocarcinoma accounts for 3% of all gastrointestinal cancers<sup>13</sup> and is the second commonest primary hepatic tumour.<sup>5,13</sup> The peak age for patients with the disease is the seventh decade and the sex incidence shows a slight male preponderance,<sup>4,11</sup> with 48% of these tumours occurring in men compared with 37% in women in a US study.<sup>14</sup> The reported incidence in the USA is 1–2 cases per 100 000 (3500 new cases per year) with no clear racial predisposition.<sup>14</sup> Of note, several studies have shown that the incidence and mortality rates of intrahepatic cholangiocarcinoma are rising, and those of extrahepatic cholangiocarcinoma are declining internationally (figure 1).<sup>5–8</sup>

### Search strategy and selection criteria

This Seminar was written after a systematic review of articles published in English, using the PubMed and Medline search engines. We searched using the key word “cholangiocarcinoma” in association with relevant areas including: reviews, epidemiology, intrahepatic, extrahepatic, aetiology, molecular markers, viral hepatitis, tumour markers, cholangiography, endoscopic ultrasound, biliary stents, PET, staging, surgery, portal vein embolisation, liver transplantation, radiotherapy, chemotherapy, photodynamic therapy and palliation. We also reviewed citations from papers from the search. Where possible, primary sources have been quoted. References were chosen based on the best evidence via clinical or laboratory studies, especially if the work had been corroborated by published work from other centres. Priority was given to studies in high impact factor journals when available.

*Lancet* 2005; 366: 1303–14

Liver Unit, Division of Medicine, St Mary's Hospital Campus, Faculty of Medicine, Imperial College London, London, UK (S A Khan PhD, H C Thomas FRCP, S D Taylor-Robinson FRCP); and Department of Surgery, Royal Free Hospital, London, UK (B R Davidson MD)

Correspondence to: Dr Shahid A Khan [shahid.khan@imperial.ac.uk](mailto:shahid.khan@imperial.ac.uk)

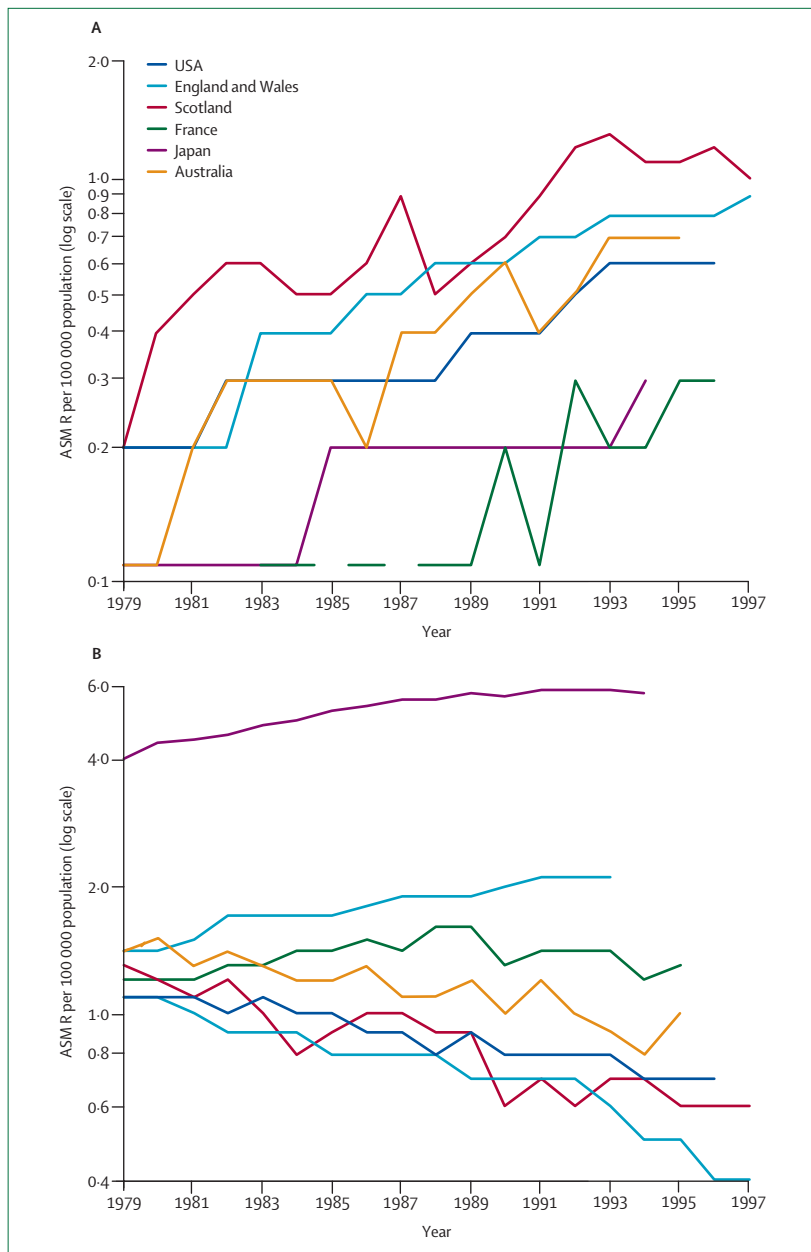


Figure 1: International age-standardised mortality rates (ASMR) for intrahepatic cholangiocarcinoma (A) and for gall bladder and extrahepatic cholangiocarcinoma (B)

### Intrahepatic cholangiocarcinoma

Incidence rates for intrahepatic cholangiocarcinoma vary substantially worldwide, reflecting the distribution of local geographic risk factors, in addition to genetic differences among various populations.<sup>4,15</sup> The highest rates occur in northeast Thailand (96 per 100 000 men), China, and other parts of southeast Asia, whereas in Australia the incidence is relatively low at 0.2 per 100 000 men.<sup>4</sup> Rising incidence rates, paralleled by mortality rates, have been documented around the world: in Europe and North America, Asia, Japan, and

Australia (figure 1).<sup>4-8</sup> In the UK, since the mid-1990s, intrahepatic cholangiocarcinoma has overtaken hepatocellular carcinoma as the leading cause of death from a primary liver tumour.<sup>5,8</sup> Researchers investigated whether the rise in intrahepatic tumour incidence represents a real increase in this tumour rather than a rise secondary to improved detection or reclassification of other hepatobiliary malignancies.<sup>16</sup> The researchers used the SEER database, which represents 10–14% of the total US population, to show that age-adjusted incidence rates of intrahepatic cholangiocarcinoma had increased by 165%, from 0.32 per 100 000 during 1975–79 to 0.85 per 100 000 during 1995–99.<sup>16</sup> As with similar studies from other countries, this rise occurred across all age-groups, especially in those older than 65 years, and in both sexes. Increased detection of a tumour is usually associated with an increase in the proportion of patients with early stage disease, or smaller sized lesions. The rise in intrahepatic cancer was not associated with a significant change in the proportion of early stage cancers, histologically confirmed tumours, or smaller sized lesions.<sup>16</sup> Furthermore, the rising incidence does not seem to be plateauing, as would be expected if it were due to an improvement in diagnostic modalities, such as endoscopic retrograde cholangiopancreatography (ERCP), MRI, or CT, which have become established practice for several years.<sup>4,5,8</sup> Also of note, the rise in intrahepatic tumours is greater than the relative decline in extrahepatic tumours.<sup>4,5</sup> These factors suggest that the increasing incidence in intrahepatic cancer is probably a true increase. The heightened incidence of this tumour is probably not due to a rise in primary sclerosing cholangitis, the main known risk factor in the western world, since incidence of primary sclerosing cholangitis is not reported to have risen and the disease is associated with the development of intrahepatic tumours in younger patients, rather than the older age-groups implicated in the epidemiological studies.<sup>4,5</sup> The cause for increasing intrahepatic cholangiocarcinoma remains unclear.

### Extrahepatic cholangiocarcinoma

Although there are few data for extrahepatic cholangiocarcinoma, incidence and mortality rates seem to be declining in many countries (figure 1). According to the SEER data, US age-standardised mortality rates for extrahepatic tumours fell from 0.6 per 100 000 in 1979 to 0.3 per 100 000 in 1998; and age-standardised incidence rates decreased from 1.08 per 100 000 to 0.82 per 100 000 in the same period.<sup>4,6</sup> Similar trends have been reported worldwide.<sup>4,5,7</sup> The data for extrahepatic cancer are perhaps more difficult to obtain because gallbladder cancers are often combined with extrahepatic cholangiocarcinoma for ICD coding purposes, and gallbladder cancers are known to be falling, probably as a result of increasing cholecystectomy rates over the past few decades.<sup>4,5,8</sup>

## Cause and risk factors for cholangiocarcinoma

Known risk factors account for only a few cases of cholangiocarcinoma and seem to be associated with chronic inflammation of the biliary epithelium.

### Primary sclerosing cholangitis

Primary sclerosing cholangitis is the commonest known predisposing condition for this cancer in the west. Cholangiocarcinoma rates of 8–40% have been reported in patients with primary sclerosing cholangitis in follow-up studies and explant specimens.<sup>4</sup> Cholangiocarcinoma in such patients tends to present earlier, in 30–50 year age-groups, than in sporadic cases.<sup>17,18</sup> About a third of patients with primary sclerosing cholangitis who develop cholangiocarcinoma do so within 2 years of diagnosis and the risk of cholangiocarcinogenesis seems unrelated to the duration of the inflammatory disease.<sup>17,19</sup> Two-thirds of patients with primary sclerosing cholangitis have associated inflammatory bowel disease, especially ulcerative colitis.<sup>17</sup> No association has been shown between the risk of cholangiocarcinoma and the presence, severity, and extent of inflammatory bowel disease in this cohort of patients.<sup>17,20</sup>

### Parasitic infection

A large body of experimental and epidemiological data suggest a pathogenic association between liver fluke infestation, especially *Opisthorcis viverrini* (and less definitively *Clonorchis sinensis*) and cholangiocarcinoma.<sup>21</sup> Most epidemiological data are from Thailand, which has the highest incidence of cholangiocarcinoma worldwide (87 per 100 000 population) and where an estimated seven million people have opisthorchiasis.<sup>22</sup> Human beings are infected by eating undercooked fish with adult worms inhabiting and laying eggs in the biliary system. Apart from a strongly positive correlation between liver flukes and cholangiocarcinoma in case-control studies,<sup>23</sup> malignant change in the biliary epithelium of Syrian hamsters has been shown after infection with *O viverrini*, especially if fed nitrosoamines.<sup>24</sup> These carcinogens are produced by bacteria in fish and other foods and are thought to act as a cofactor in cholangiocarcinogenesis.

### Fibropolycystic liver disease

Congenital abnormalities of the biliary tree associated with Caroli's syndrome, congenital hepatic fibrosis, and choledochal cysts (cystic dilatations of the bile ducts) carry a 15% risk of malignant change after the second decade, at an average age of 34 years.<sup>25</sup> The overall incidence of cholangiocarcinoma in patients with untreated cysts is up to 28%.<sup>26,27</sup> The mechanism of carcinogenesis is unclear, but could be related to biliary stasis, reflux of pancreatic juice causing chronic inflammation, activation of bile acids,<sup>28</sup> and deconjugation of carcinogens. Bile duct adenomas and biliary

papillomatosis are also associated with the development of cholangiocarcinoma.

Bile salt transporter protein polymorphisms in BSEP, FIC1, and MDR3 genes can lead to unstable bile content and to deconjugation of xenobiotics, previously conjugated in the liver.<sup>29–31</sup> On the background of congenital bile duct abnormalities, this process can lead to the development of cholangiocarcinoma at an early stage in life.<sup>32</sup> We speculate that individuals who are heterozygous for bile salt transporter polymorphisms have an increased predisposition to cholangiocarcinoma as adults, after exposure to cofactors that result in chronic inflammation in the biliary tree.

### Intrahepatic biliary stones

Hepatoithiasis is rare in the west, but relatively common in parts of Asia, and is associated particularly with peripheral intrahepatic cholangiocarcinoma.<sup>4</sup> Up to 10% of patients with hepatoithiasis develop cholangiocarcinoma.<sup>33</sup> In Taiwan, up to 70% of patients with cholangiocarcinoma undergoing resection reportedly have intrahepatic biliary stones, and in Japan this figure is 6–18%.<sup>34,35</sup> Biliary stones are thought to cause bile stasis, predisposing to recurrent bacterial infections and subsequent inflammation, a potential cofactor for cholangiocarcinogenesis.

### Chemical carcinogen exposure

Several chemical toxins have been associated with cholangiocarcinoma. Promutagenic DNA adducts have been identified in cholangiocarcinoma tissue, indicating exposure to DNA-damaging agents.<sup>36</sup> Thorotrast, a radiological contrast agent banned in the 1960s for its carcinogenic properties, has been strongly associated with the development of cholangiocarcinoma many years after exposure, increasing the risk to 300 times that of the general population.<sup>4,37</sup> Associations have also been made with exposure to by-products from the rubber and chemical industries, including dioxins and nitrosamines,<sup>38</sup> as well as with alcohol and smoking,<sup>19,20</sup> but results have been conflicting and no firm conclusions can as yet be drawn.

### Viral hepatitis

Cirrhosis, of any cause, has also been associated with cholangiocarcinoma.<sup>14,39</sup> A cohort study of over 11 000 patients with cirrhosis, followed up over 6 years, showed a 10-fold risk compared with the general population.<sup>39</sup> More specifically, hepatitis B and C viruses have been linked to the cancer. A case-control study from Korea reported that 12.5% of patients with cholangiocarcinoma tested positive for hepatitis C virus and 13.8% for hepatitis B virus surface antigen (HBsAg), compared with 3.5% and 2.3% of controls.<sup>40</sup> In a second case-control study from Italy, 23% of patients with cholangiocarcinoma were positive for anti-hepatitis C virus and 11.5% were HbsAg-positive

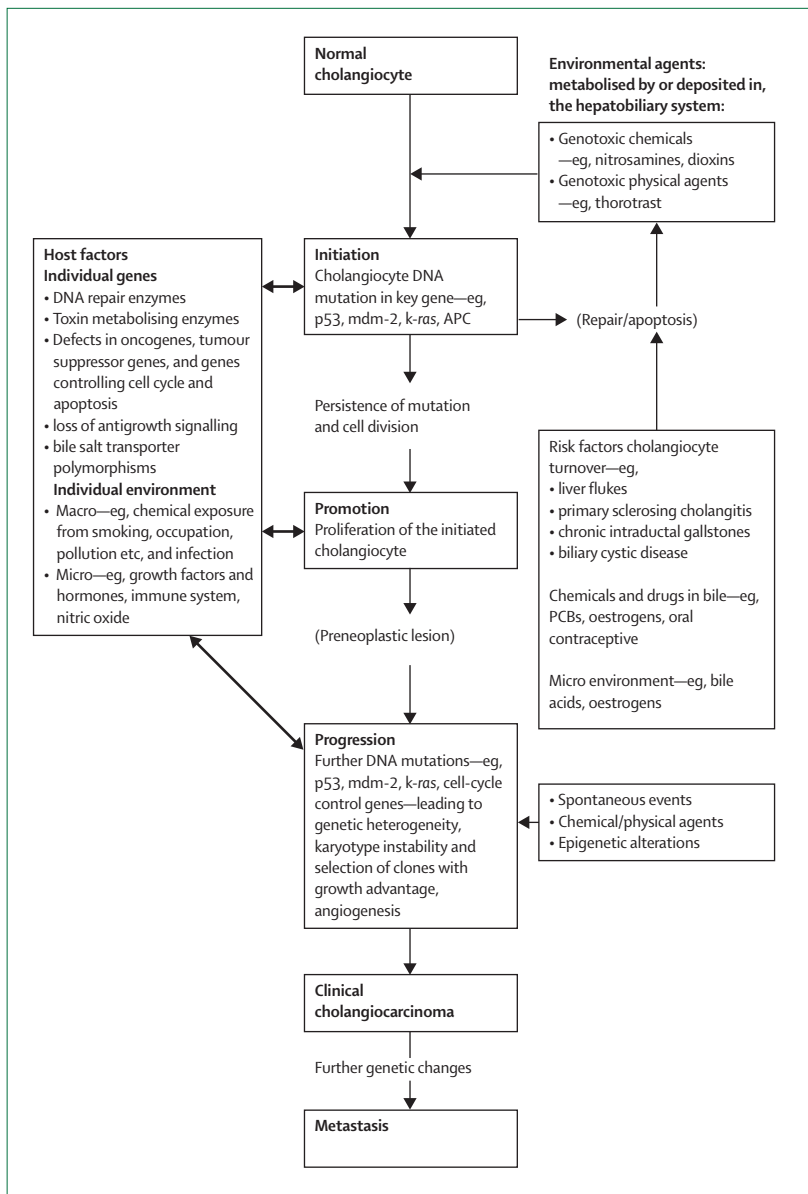


Figure 2: Proposed model for carcinogenesis in cholangiocarcinoma showing interaction between environmental factors and host genetics

compared with 6% and 5.5% of controls, respectively.<sup>41</sup> A prospective controlled study from Japan reported the risk of developing cholangiocarcinoma in patients with cirrhosis related to hepatitis C virus as 3.5% at 10 years, 1000 times greater than in the general population.<sup>42</sup> Hepatitis C virus is an established risk factor for hepatocellular carcinoma and both hepatocytes and cholangiocytes have the same progenitor cell, supporting a role for the virus in cholangiocarcinogenesis. Furthermore, RNA from hepatitis C virus has been identified in cholangiocarcinoma tissue.<sup>43</sup> A US case-controlled study of risk factors for intrahepatic cholangiocarcinoma showed adjusted odds

ratios of 6.1 for hepatitis C virus, and 5.9 for HIV infection. Diabetes was also prevalent in intrahepatic tumours (adjusted odds ratio 2.0), but pathogenic mechanisms are unclear.<sup>14</sup>

### Molecular pathogenesis and markers

A number of mutations in oncogenes and tumour suppressor genes have been identified in cholangiocarcinoma,<sup>44</sup> suggesting the cancer may arise secondary to cellular, and consequent DNA, injury. Several studies have shown abnormal expression of the *K-ras* oncogene in 21–100% of cases and the *p53* tumour suppressor gene in up to 37% of archival specimens in the largest studies.<sup>45</sup> These genetic alterations are associated with a more aggressive phenotype in this cancer.<sup>45,46</sup> *K-ras* and *p53* mutations have also been identified in bile and pancreatic juice of affected patients.<sup>45,47</sup> Neither *K-ras* nor *p53* mutational analysis have been shown to be superior to conventional cytopathology in the diagnosis of pancreaticobiliary tumours, but combined analysis of both can increase sensitivity in tissue biopsy and bile specimens.<sup>45,47,48</sup> Increased expression of *c-met* and *c-erbB-2* proto-oncogenes has been shown and they have been suggested to participate in the metastatic transformation of intrahepatic tumour.<sup>49</sup> Over expression of the proto-oncogene *Bcl-2* has been reported to reduce apoptosis in cholangiocarcinoma cell-lines.<sup>50</sup> Although human cholangiocarcinoma does not express *Bcl-2*, other anti-apoptotic proteins, *mcl-1* and *Bcl-xl*, are expressed.<sup>51</sup> Point mutations leading to promoter methylation of cell cycle regulators *p16<sup>INK4a</sup>* and *p14<sup>ARF</sup>* have also been identified in cholangiocarcinoma related to primary sclerosing cholangitis.<sup>52</sup> Other potential molecular markers for biliary malignancy are currently under investigation. These include growth factors and the occurrence of DNA aneuploidy, nuclear morphometry, and loss of heterozygosity of microsatellite markers.<sup>45</sup>

### Carcinogenesis in cholangiocarcinoma

Development of cholangiocarcinoma, as with most tumours, is probably a multi-step process dependent on an interaction between environmental factors and host genetic factors. Most of the putative environmental risk factors for cholangiocarcinoma cause chronic biliary irritation and can contribute to a promotional stage of carcinogenesis. Several of the potential genetic changes<sup>44</sup> in the host that could be implicated in cholangiocarcinogenesis are summarised in figure 2. Genetic polymorphisms in the cytochrome P450 enzymes or in the bile salt transporter proteins, for example, could lead to alterations in the efficiency with which environmental toxins (xenobiotics) are handled by the liver. The development of cholangiocarcinoma probably needs a “second hit” to deconjugate such xenobiotics and to expose the bile duct epithelium to damage. Such secondary hits include chronic inflammation, viral hepatitis, worm infections, and recurrent cholangitis.

### Clinical features

Cholangiocarcinoma is rare in individuals younger than 40 years. The presenting clinical features depend on tumour location. Lesions at the bifurcation of the hepatic ducts or in the distal common bile duct classically present with the sequelae of biliary obstruction: painless jaundice, pale stools, dark urine, and pruritus.<sup>11</sup> Peripheral tumours, arising within intrahepatic ducts of the liver parenchyma itself, tend to present with non-specific symptoms such as malaise, weight loss, and abdominal pain. Cholangitis is an unusual presentation. Patients with primary sclerosing cholangitis and cholangiocarcinoma tend to present with a rapid fall in performance status and increasing cholestasis.<sup>53</sup>

### Diagnosis

Most patients with hilar strictures and jaundice have cholangiocarcinoma.<sup>54</sup> However, confirmation of cholangiocarcinoma can be very difficult because of a wide range of alternative diagnoses, including benign strictures (iatrogenic bile duct injuries, primary sclerosing cholangitis, and choledocholithiasis); and other carcinomas, such as gallbladder cancer or metastatic hilar nodal metastases. The diagnosis of cholangiocarcinoma occurring in primary sclerosing cholangitis can be especially challenging as mass lesions are infrequently identified on imaging and patients often do not develop significant intrahepatic biliary tree dilatation, particularly with dominant strictures in those with a background of secondary biliary cirrhosis.<sup>53</sup> A high index of suspicion and multidisciplinary investigative approaches are needed.<sup>55</sup> In particular, a diagnosis of intrahepatic cholangiocarcinoma should be actively considered in patients with a liver mass histologically confirmed to be an adenocarcinoma without an obvious primary source.

### Biochemical investigations

Obstructive jaundice typically results in a non-specific rise in serum bilirubin and the liver enzymes alkaline phosphatase and gamma-glutamyl transpeptidase, but it is not uncommon for the transaminase concentrations to also increase. There are no tumour markers specific for cholangiocarcinoma. However, several are useful as a diagnostic guide. The most commonly used are carbohydrate antigen (CA) 19-9 and carcinoembryonic antigen (CEA).

The estimated sensitivity of CA 19-9 in predicting cholangiocarcinoma in the context of primary sclerosing cholangitis is 38–89% with a specificity of 50–98%.<sup>45</sup> In a series of patients without primary sclerosing cholangitis, the sensitivity of CA 19-9 concentrations of more than 100 U/mL in diagnosing cholangiocarcinoma was 53%.<sup>56</sup> When compared with non-malignant liver disease and benign bile duct strictures, the specificity rates were 76% and 92%, respectively.<sup>56</sup> However, CA 19-9 has similar sensitivity and specificity for pancreatic cancer and is

also raised in colorectal, gastric, and gynaecological malignancies<sup>57</sup> as well as in cholangitis.<sup>58</sup>

CEA is primarily a marker for colorectal cancer. Alone, it has unsatisfactory sensitivity and specificity for cholangiocarcinoma.<sup>45,59</sup> Some reports suggest cholangiocarcinoma detection rates, in the setting of primary sclerosing cholangitis, may increase if CEA and CA 19-9 are combined in a diagnostic algorithm.<sup>59,60</sup> However, these results have generally not been reproducible. Several new and potentially useful tumour markers are currently being studied, with no clear data yet. These include CA50, CA 242, CA 195, RCAS1, and DU-PAN-2.<sup>45</sup>

Both CEA and CA 19-9 have been measured in bile from patients with benign and malignant diseases of the pancreaticobiliary tract, but results are contradictory and no consistent differences have been found.<sup>45</sup>

### Radiological investigations

Imaging is essential for diagnosis and planning of treatment. The primary investigation for suspected cholangiocarcinoma is a transabdominal ultrasound scan, which is highly sensitive for confirming biliary duct dilatation, localising the site of obstruction and excluding gallstones.<sup>61</sup> Intrahepatic duct dilatation with normal diameter extrahepatic ducts is seen with proximal (hilar) lesions. With distal lesions, both intrahepatic and extrahepatic ducts are dilated.<sup>61</sup>

Contrast-enhanced, triple phase, helical CT is very sensitive for detecting intrahepatic cholangiocarcinomas of greater than 1 cm, locating the level of biliary obstruction and the presence of lymphadenopathy.<sup>62</sup> However, resectability might only be established in as few as 60% of cases.<sup>63</sup> Dynamic CT could improve this figure.

Magnetic resonance cholangiopancreatography (MRCP) has several potential advantages over CT. As well as identifying intrahepatic mass lesions, the technique can provide a three-dimensional computerised reconstruction of the biliary tree allowing assessment of bile ducts, both above and below a stricture. The non-invasively acquired cholangiographic images obtained at MRCP are comparable to invasive cholangiographies (endoscopic retrograde cholangiopancreatography [ERCP] and percutaneous transhepatic cholangiopancreatography [PTC]), with high positive and negative predictive values for detecting the level and features of biliary obstructions.<sup>63–66</sup> Owing to intrinsically high tissue contrast and multiplanar capability, MRCP is probably superior to ERCP for defining the anatomy of tumours and assessing resectability, and is increasingly becoming the imaging modality of choice.<sup>11,65</sup> Important factors, such as the extent of bile duct invasion, vessel encasement, invasion of adjacent liver parenchyma by hilar cholangiocarcinomas, local lymphadenopathy, and distant metastases, can be assessed.<sup>65</sup> MRCP has the further advantage over ERCP, in that undrained bile ducts can be visualised without

**Panel: TNM system for cholangiocarcinoma staging**

Stage 0	T <sub>is</sub>	N <sub>0</sub>	M <sub>0</sub>
Stage I	T <sub>1</sub>	N <sub>0</sub>	M <sub>0</sub>
Stage II	T <sub>2</sub>	N <sub>0</sub>	M <sub>0</sub>
Stage III	T <sub>1</sub> or T <sub>2</sub>	N <sub>1</sub> or N <sub>2</sub>	M <sub>0</sub>
Stage IVA	T <sub>3</sub>	Any N	M <sub>0</sub>
Stage IVB	Any T	Any N	M <sub>1</sub>

T<sub>is</sub>: carcinoma in situ. T<sub>1</sub>: invasion of subepithelial connective tissue. T<sub>2</sub>: invasion of perifibromuscular connective tissue. T<sub>3</sub>: invasion adjacent organs.

N<sub>0</sub>: no regional lymph nodes. N<sub>1</sub>: metastasis to hepatoduodenal ligament lymph nodes. N<sub>2</sub>: metastasis to peripancreatic, periduodenal, periportal, coeliac and/or superior mesenteric artery lymph nodes.

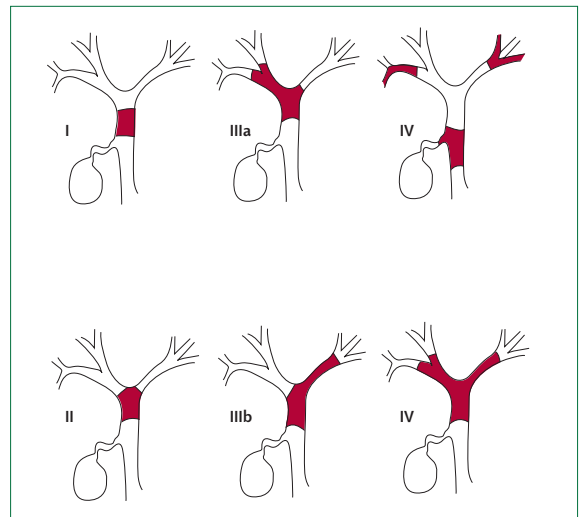
M<sub>0</sub>: no distant metastasis. M<sub>1</sub>: distant metastasis.

injection of contrast, thus avoiding the risk of cholangitis.<sup>65</sup> However, that the correlation between MRCP findings and the extent of cholangiocarcinoma suggests that MRCP understages disease in up to 20% of malignant hilar strictures should be noted.<sup>67</sup>

The choice between PTC and ERCP is largely dependent on local expertise, availability, and failure of one or other technique, usually ERCP. Anatomical characteristics are also important.<sup>11</sup> For example, proximal lesions can often be unsatisfactorily accessed by ERCP for diagnosis and therapy. The main advantage these techniques have over MRCP is that washings, brushings, and even intraductal biopsies can be obtained for cytopathological analysis. Additionally, therapeutic drainage can be undertaken. Although the diagnostic yield obtained from cytology is low,<sup>11</sup> sensitivity could be increased by new analysis techniques, such as digital image analysis and fluorescent in-situ hybridisation.<sup>68</sup> The main disadvantage of these invasive techniques is the associated procedural risks including duodenal perforation, biliary leakage, bleeding, and pancreatitis.

At presentation up to 50% of patients with cholangiocarcinoma have lymphadenopathy, which is often missed on preoperative imaging.<sup>11</sup> Endoscopic ultrasound can be useful in identifying local lymph node enlargement and allows fine needle aspiration of the tumour mass or surrounding lymph nodes. Endoscopic ultrasound with fine needle aspiration has a greater sensitivity for detecting malignancy than ERCP with brushings.<sup>70</sup> The technique also avoids contamination of the biliary tree, which can occur with ERCP.<sup>70</sup>

PET scanning with the focal accumulation of nucleotide tracer 18-fluorodeoxyglucose (FDG) is an emerging staging technique for many cancers. The technique can detect nodular cholangiocarcinomas as



**Figure 3: Bismuth classification of biliary strictures<sup>72</sup>**

Type I: tumours below the confluence of the left and right hepatic ducts. Type II: tumours reaching the confluence but not involving left or right hepatic ducts. Type III: tumours occluding the common hepatic duct and either the right (IIIa) or the left (IIIb) hepatic duct. Type IV: tumours that are multi-centric or involving both right and left hepatic ducts.

small as 1 cm, but is less helpful for infiltrating tumours.<sup>71</sup> A study of 30 patients with extrahepatic cholangiocarcinoma compared FDG-PET scan with CT for initial staging.<sup>72</sup> Tumours were interpreted as malignant on the basis of CT in 24 (80%) patients, while FDG-PET revealed increased FDG uptake in 18 (60%) patients. With respect to lymphadenopathy, there was no difference in sensitivity between the two techniques, but FDG-PET had a specificity of 100% compared with 59% for CT ( $p < 0.01$ ).<sup>72</sup> A retrospective study assessed FDG-PET scans in 21 patients with intrahepatic cholangiocarcinoma (both hilar and peripheral) who had undergone CT and MRI.<sup>73</sup> For the detection of lymph node metastasis, FDG-PET and CT and MRI were concordant in 16 patients and discordant in five (FDG-PET was positive in three, and CT and MRI in two). FDG-PET identified unsuspected distant metastases in four patients, all of whom had peripheral cholangiocarcinoma.<sup>73</sup> The ability of PET to detect distant metastases could alter the surgical management plan in up to 30% of cases.<sup>71,74</sup>

### Clinical staging

Cholangiocarcinoma staging is based on the tumour-node-metastasis (TNM) system (panel). Furthermore, the extent of duct involvement by perihilar tumours can be classified according to the Bismuth classification (figure 3), which stratifies patients on location and extent of cancer in the biliary tree.<sup>75</sup>

### Surgical management

A complete surgical resection with histologically negative resection margins is the only cure for

cholangiocarcinoma. Unfortunately only a few patients are suitable for surgery and therefore early liaison with a specialist surgical team is recommended.<sup>11</sup> The nature and extent of the surgery depends on the site of the cancer within the liver or the biliary tract. For extrahepatic cholangiocarcinoma affecting the common bile duct, the biliary tree and hilar lymphatics are resected.<sup>54</sup> Most patients with extrahepatic tumour where the confluence of the bile ducts is also affected, will additionally need a partial hepatectomy to adequately resect the cancer.<sup>54</sup> Hilar (Klatskin) tumours often involve the principal caudate duct and the caudate lobe (segment 1) is also resected with these cancers. Distal cholangiocarcinomas are managed by pancreatoduodenectomy (Whipple's procedure), as with ampullary or pancreatic head cancers,<sup>11</sup> again the aim being a margin-negative resection.

#### Assessment of resectability

Assessment of resectability should start immediately after the diagnosis of cholangiocarcinoma is considered and before instrumentation with ERCP or PTC or before stent insertion produces inflammation or infection rendering assessment, and subsequent surgery, more difficult.<sup>11,55</sup>

The possibility of metastatic disease producing biliary obstruction should be excluded by imaging the chest, abdomen, and pelvis because cholangiocarcinomas are adenocarcinomas and lack specific pathognomonic findings on histological analysis. Patients who are considered for surgery are medically fit, have disease which can be resected with clear margins, and have no evidence of metastases.<sup>54,76,77</sup> Involvement of the main hepatic artery or portal vein is the most common contraindication to resection although some centres support en bloc resection with vascular reconstruction.<sup>78</sup> Extension of cholangiocarcinoma to involve segmental bile ducts on both liver lobes (Bismuth 4) also contraindicates resection. Other local factors that affect resectability include lobar atrophy.<sup>77</sup> Peritoneal and superficial liver metastases are rarely detected with current imaging and laparoscopy has identified additional disease in up to a third of cases in some series.<sup>54,79</sup> Factors affecting postoperative outcome include comorbidity, hyperbilirubinaemia, and the risk of postoperative liver failure, nutritional status, and hypoalbuminaemia.<sup>54,80</sup>

#### Survival post-surgery

After resection, 5-year survival rates for intrahepatic cholangiocarcinomas vary from 8% to 47% with the highest survival in patients with negative resection margins.<sup>54,80-83</sup> The increasingly radical approach to resection for cholangiocarcinoma over the past 10 years has resulted in an increased proportion of patients with negative resection margins and a consequent improvement in 5-year survival.<sup>55,83</sup> However, perioperative

mortality also rises with more extensive operations compared with wide local excisions (10% vs 4%, in one study).<sup>83-87</sup> For distal cholangiocarcinomas, 5-year survival rates of 20-54% have been reported in selected patients managed by pancreatoduodenectomy.<sup>88,89</sup> Regional lymph node metastases are common with hilar cholangiocarcinoma (up to 35% in a recent series),<sup>90</sup> but there is no evidence that extended lymph node dissection improves survival.

#### Preoperative biliary drainage

Preoperative biliary drainage is associated with an increased risk of cholangitis and lengthened postoperative hospital stay, but unrelieved biliary obstruction runs the risk of cholestasis and liver failure.<sup>55</sup> In a study of 28 patients with hilar cholangiocarcinoma who underwent surgical curative therapy, no significant differences were shown in morbidity or mortality for patients with and without preoperative biliary drainage.<sup>91</sup> Preoperative biliary drainage is unproven as a routine, but should be done in septic and high risk patients.<sup>11,55</sup>

#### Portal vein embolisation

Selective ipsilateral portal vein embolisation before resection can induce a compensatory hypertrophy of the future remnant liver, thereby reducing liver dysfunction after resection. This technique could benefit patients needing extensive liver resection with a predicted future liver remnant volume of less than 25%.<sup>84,92,93</sup> Both preoperative biliary drainage and portal vein embolisation are controversial and further controlled studies are needed.

#### Adjuvant radiotherapy

External beam irradiation has been used with or without iridium-192 (<sup>192</sup>Ir) brachytherapy. A small retrospective series showed an increased 5-year survival in patients with margin-positive resections receiving postoperative external beam radiotherapy (34% vs 13.5%).<sup>94</sup> However, these results have not been supported by other studies and there is a lack of prospective randomised trials.<sup>95,96</sup> There is no evidence to lend support to the use of adjuvant radiotherapy in patients with margin-negative resections.<sup>96</sup>

#### Adjuvant chemotherapy

Chemotherapy has so far not been shown to substantially improve survival in patients with resected or unresected cholangiocarcinoma.<sup>55</sup> Most studies have used 5-fluorouracil (5-FU) alone or in combination with agents such as methotrexate, cisplatin, mitomycin C, leucovorin, and interferon alpha, which have been given by a variety of routes including systemic, hepatic arterial, and intraductal infusions. Most studies are small, retrospective, and single-centred, resulting in poor quality data. There is currently no role for adjuvant chemotherapy outside a trial setting.<sup>11,55</sup>

### Adjuvant chemoradiation therapy

The potential radiosensitising effect of 5-FU suggests that combination of radiation and chemotherapy would be more effective than either alone. This approach has been used in some early studies with encouraging results.<sup>55</sup> However, there are no prospective trials of this combined treatment and a retrospective case study showed no benefit with adjuvant chemoradiation therapy.<sup>91</sup>

### Liver transplantation

Liver transplantation for unresectable cholangiocarcinoma is currently contraindicated because of a high recurrence rate of up to 90% within 2 years.<sup>97,98</sup> However, trials in highly selected patients with new adjuvant and neoadjuvant protocols have shown encouraging results. A study from the Mayo Clinic treated 28 patients with unresectable, stage I/II perihilar cholangiocarcinoma and negative staging laparotomy with external-beam irradiation, systemic 5-FU, and brachytherapy with <sup>192</sup>Ir plus oral capecitabine before liver transplantation.<sup>99</sup> Of note, a third of the originally recruited patients were shown, at staging laparotomy, to have previously undetected regional lymphadenopathy, local disease extension, or perihilar implants and did not undergo transplantation. Of the 28 receiving a liver transplant, three died from perioperative complications and four developed recurrent cholangiocarcinoma 22–63 months later.<sup>99</sup> Overall 5-year survival was 82%, which is comparable to overall results for liver transplantation across the USA and is better than surgical resection survival rates.<sup>99</sup> These results are promising and would support further clinical trials to optimise patient selection and chemoradiotherapy regimens.

### Palliation

Palliative treatment to relieve symptoms, treat sepsis, or normalise bilirubin before chemotherapy or radiotherapy, clearly has an important role given that 80% of patients with hilar cholangiocarcinoma are unsuitable for resection and even in those undergoing resection there is a high risk of recurrence.<sup>77,86</sup> Median survival for non-resectable cholangiocarcinomas is about 3 months without and 6 months with biliary drainage.<sup>100–102</sup> Bacterial cholangitis or liver failure often contribute to death.

### Palliative surgical biliary drainage

Surgical biliary drainage can be achieved by creating a biliary-enteric bypass. The main advantage is that lifelong patency is usually achieved.<sup>103</sup> The disadvantages include increased morbidity, mortality, cost, and recovery time associated with major surgery. Studies comparing surgical with non-surgical biliary drainage show similar palliation and survival.<sup>104</sup> The main indication is in selected patients who are judged to have

a favourable prognosis. Palliative surgical drainage for distal cholangiocarcinomas is technically simpler than for proximal lesions.

### Palliative endoscopic biliary drainage

The aims of palliative endoscopic biliary drainage are to relieve jaundice and pruritus, prevent cholangitis, avoid liver failure due to progressive biliary obstruction, and to enhance quality of life.<sup>70</sup> Patency rates are generally higher for distal tumours compared with hilar lesions,<sup>105</sup> which often need two or more stents for adequate drainage.<sup>106</sup> Endoscopic biliary drainage can be achieved by plastic (polyethylene) or metal stents. Percutaneous insertion of a biliary stent can be preferable for hilar (Klatskin) tumours as the stent placement is more predictable than with an endoscopic approach. Self-expanding metal stents are increasingly favoured. They are successful in most cases of hilar obstruction,<sup>55,70</sup> and although individually more expensive, metal stents have a larger diameter and stay patent longer than plastic stents, thus needing fewer repeat procedures.<sup>107</sup> Self-expanding metal stents are also associated with lower hospitalisation rates and reduced duration of antibiotic treatment, although there is no significant difference in survival between plastic and metal stents. Overall metal stent placement is the most cost-effective treatment of inoperable malignant common bile duct strictures, especially for patients without hepatic metastases who are expected to survive longer (3–6 months).<sup>107</sup> Plastic stents should be placed in patients who are thought to have a shorter life expectancy.<sup>11,107</sup> Tissue confirmation of cancer should always be obtained before placement of self-expanding metal stents as these stents cannot be removed, except at operation.

### Unilateral versus bilateral stents

Single or multiple biliary stents can be placed depending on the extent of the stricture. Single stents are adequate for strictures of the main bile duct below the confluence (Bismuth I lesions). However, for hilar or Bismuth II–IV strictures, there is controversy as to whether single or double stents should be inserted. Given that only about 25% of the liver needs to be drained for adequate palliation, a single stent into one lobe of the liver should suffice in the absence of biliary tract sepsis.<sup>70,108</sup>

Several studies have compared unilateral and bilateral drainage in hilar cholangiocarcinomas. A study of 48 patients showed that bilateral stent insertion was associated with increased survival (176 vs 119 days) and reduced the risk of cholangitis.<sup>109</sup> However, both lobes of the liver were injected with contrast in all patients, thus increasing the risk of cholangitis in patients who only received one stent compared with those patients with bilateral stents who had both lobes subsequently drained of contrast.<sup>70</sup> A prospective randomised

controlled trial comparing unilateral versus bilateral stents found that unilateral stents achieved a higher success rate for stent insertion (89% vs 77%) and drainage (81% vs 73%) with a lower early complication rate (19% vs 27%).<sup>110</sup> There was no difference with respect to procedure related mortality, late complications, or survival suggesting that a unilateral stent is likely to suffice in most cases.<sup>110</sup>

Plastic stents in the hilum are prone to distal migration. Recent studies support selective unilateral drainage of hilar tumours with self-expanding metal stents with the help of MRCP or CT imaging.<sup>111,112</sup> Imaging allows optimal lobe and biliary segments to be chosen, thereby reducing the need to inject contrast into multiple segments at ERCP and thus diminishing the risk of post-ERCP cholangitis.<sup>70</sup>

#### Covered versus uncovered stents

Tumours can invade self-expanding metal stents through the metallic mesh. This can be prevented by covering stents with non-porous membranes, such as polyurethane. A prospective, multi-centre, randomised controlled trial compared covered and uncovered diamond stents in 112 patients with unresectable distal malignant biliary obstruction.<sup>113</sup> Stent occlusion was significantly lower in the covered stent group (14% vs 38%) than in the uncovered stent group.<sup>113</sup> Covered stents were also more cost effective. However, there was no difference in survival and only distal tumours were assessed, which are easier to palliate. Covered stents might not be appropriate for hilar strictures as biliary side branches could be obstructed.<sup>114</sup>

#### Palliative radiotherapy

Palliative radiotherapy might be suitable for patients with unresectable, locally advanced disease, in the absence of distant metastases, by contributing to biliary decompression and pain relief.<sup>94,115</sup> Studies have returned mixed results using external beam radiotherapy with or without intraluminal <sup>192</sup>Ir seeds, endoscopically or percutaneously mounted on a catheter and placed across a stricture. Survival benefit is debatable and there are no controlled studies. Intraluminal brachytherapy can further increase the risk of complications secondary to cholangitis.<sup>116</sup>

#### Palliative chemotherapy

Response rates with palliative chemotherapy are poor and there is no proven survival benefit over biliary drainage alone.<sup>55,117</sup> Some reports of 5-FU in combination with agents such as etoposide and leucovorin have shown partial responses—comparable to other chemosensitive tumours—eg, gastric cancers—as assessed by objective tumour shrinkage and disease stabilisation (table).<sup>118–126</sup> Preliminary data suggest gemcitabine, docetaxel, and a rebeccamycin analogue, could also have activity against cholangiocarcinoma.

Drug combination	Patients (n)	Partial response rate/stable disease
5-FU 1 leucovorin <sup>117</sup>	28	32%
5-FU 1 cisplatin <sup>118</sup>	25	24%
5-FU 1 epirubicin 1 cisplatin <sup>119</sup>	25	40%
5-FU 1 leucovorin 1 oxaliplatin <sup>120</sup>	16	56%
5-FU 1 gemcitabine 1 leucovorin <sup>121</sup>	36 vs 22% (gemcitabine alone)	
Docetaxel (phase II trial) <sup>122</sup>	25	20%
Rebeccamycin analogue (phase II trial) <sup>123</sup>	27	45%
Gemcitabine 1 cisplatin <sup>124</sup>	43	33%
Gemcitabine 1 capecitabine <sup>125</sup>	24	73%

**Table: Palliative chemotherapy studies**

#### Photodynamic therapy

In this novel treatment, the photosensitiser sodium porfimer (which localises to mitochondria) is given intravenously and localises preferentially in tumour tissue over 24–48 h. This process is followed by endoscopic direct illumination of the tumour bed with a specific wavelength of light resulting in the activation of the porfimer, generating oxygen free radicals and leading to ischaemic cancer cell death.<sup>101</sup> This technique has been shown to regress carcinomas of the skin, lungs, pharynx, oesophagus, and stomach.<sup>101</sup> The tumoricidal tissue penetration achieved is a depth of 4 mm and hence it is regarded as a palliative option. The estimated time to tumour progression is about 6 months, meaning that photodynamic therapy is needed twice yearly.<sup>101</sup>

In a prospective study, 39 patients with Bismuth III/IV cholangiocarcinomas were randomised to treatment with either biliary stenting plus photodynamic therapy or stenting alone.<sup>127</sup> The photodynamic therapy group had higher median survival (493 days vs 98 days), less cholestasis, better quality of life scores, and better stabilisation of Karnofsky performance status than did the stenting group.<sup>127</sup> The improved survival was probably secondary to relief of obstruction rather than a reduction in tumour mass.<sup>101</sup> Further studies are needed, especially of photodynamic therapy in combination with radiation or chemotherapy, or both.

#### Summary

Cholangiocarcinoma is a predominantly fatal cancer, which can be difficult to diagnose and to treat. The incidence is increasing worldwide and its pathogenesis remains unclear. New imaging and staging techniques help select patients for curative resection and can eventually define patients suitable for liver transplantation within chemoradiotherapy protocols. Chemotherapy and radiotherapy results have so far been disappointing. Palliation involves endoscopic or percutaneous stent placement for most patients, with those regarded as having favourable long-term outcome being considered for surgical bypass. Photodynamic therapy has shown promising results and recruitment to trials combining chemotherapy with photodynamic therapy should be encouraged.

**Conflict of interest statement**

We declare that we have no conflict of interest.

**Acknowledgments**

This was a commissioned Seminar. The authors received no funding for writing this article except for a small payment from *The Lancet*.

**References**

- Olnes MJ, Erlich R. A review and update on cholangiocarcinoma. *Oncology* 2004; **66**: 167–79.
- Ishak KG, Anthony PP, Sobin LH. Histological typing of tumours of the liver. WHO International Histological Classification of Tumours. Berlin: Springer Verlag, 1994.
- Carriaga MT, Henson DE. Liver, gallbladder, extrahepatic bile ducts, and pancreas. *Cancer* 1995; **1**: 75: 171–90.
- Shaib Y, El-Serag HB. The epidemiology of cholangiocarcinoma. *Semin Liver Dis* 2004; **24**: 115–25.
- Khan SA, Taylor-Robinson SD, Toledano MB, Beck A, Elliott P, Thomas HC. Changing international trends in mortality rates for liver, biliary and pancreatic tumours. *J Hepatol* 2002; **37**: 806–13.
- Patel T. Increasing incidence and mortality of primary intrahepatic cholangiocarcinoma in the United States. *Hepatology* 2001; **33**: 1353–57.
- Patel T. Worldwide trends in mortality from biliary tract malignancies. *BMC Cancer* 2002; **2**: 10.
- Taylor-Robinson SD, Toledano MB, Arora S, et al. Increase in mortality rates from intrahepatic cholangiocarcinoma in England and Wales 1968–1998. *Gut* 2001; **48**: 816–20.
- Ishak KG, Anthony PP, Sobin LH. Histological typing of tumours of the liver. WHO International Histological Classification of Tumours. Berlin: Springer Verlag, 1994.
- Nakeeb A, Pitt HA, Sohn TA, et al. Cholangiocarcinoma: a spectrum of intrahepatic, perihilar, and distal tumors. *Ann Surg* 1996; **224**: 463–73.
- Khan SA, Davidson BR, Goldin R, et al. Guidelines for the diagnosis and management of cholangiocarcinoma. *Gut* 2002; **51**, S6: V11–V19.
- Liver Cancer Study Group of Japan. The general rules for the clinical and pathological study of primary liver cancer, 4th edn. Tokyo: Kanehira, 2000.
- Vauthey JN, Blumgart LH. Recent advances in the management of cholangiocarcinomas. *Semin Liver Dis* 1994; **14**: 109–14.
- Shaib YH, El-Serag HB, Davila JA, Morgan R, McGlynn KA. Risk factors of intrahepatic cholangiocarcinoma in the United States: a case-control study. *Gastroenterology* 2005; **128**: 620–26.
- Tullo A, D'Erchia AM, Honda K, et al. New p53 mutations in hilar cholangiocarcinoma. *Eur J Clin Invest* 2000; **30**: 798–803.
- Shaib YH, Davila JA, McGlynn K, El-Serag HB. Rising incidence of intrahepatic cholangiocarcinoma in the United States: a true increase? *J Hepatol* 2004; **40**: 472–77.
- Broome U, Olsson R, Loof L, et al. Natural history and prognostic factors in 305 Swedish patients with primary sclerosing cholangitis. *Gut* 1996; **38**: 610–15.
- Pitt HA, Dooley WC, Yeo CJ, Cameron JL. Malignancies of the biliary tree. *Curr Probl Surg* 1995; **32**: 1–90.
- Bergquist A, Glaumann H, Persson B, Broome U. Risk factors and clinical presentation of hepatobiliary carcinoma in patients with primary sclerosing cholangitis: a case-control study. *Hepatology* 1998; **27**: 311–16.
- Chalasanani N, Baluyut A, Ismail A, et al. Cholangiocarcinoma in patients with primary sclerosing cholangitis: a multicenter case-control study. *Hepatology* 2000; **31**: 7–11.
- Watanapa P, Watanapa WB. Liver fluke-associated cholangiocarcinoma. *Br J Surg* 2002; **89**: 962–70.
- Watanapa P. Cholangiocarcinoma in patients with opisthorchiasis. *Br J Surg* 1996; **83**: 1062–64.
- Parkin DM, Srivatanakul P, Khlat M, et al. Liver cancer in Thailand I: a case-control study of cholangiocarcinoma. *Int J Cancer* 1991; **48**: 323–28.
- Thamavit W, Bhamarapravati N, Sahaphong S, Vajrasthira S, Angsubhakorn S. Effects of dimethylnitrosamine on induction of cholangiocarcinoma in *Opisthorchis viverrini*-infected Syrian golden hamsters. *Cancer Res* 1978; **38**: 4634–39.
- Simeone DM. Gallbladder and biliary tree: anatomy and structural anomalies. In: Yamada T, ed. Textbook of gastroenterology. Philadelphia: Lippincott Williams and Wilkins, 1999: 2244–57.
- Scott J, Shousha S, Thomas HC, Sherlock S. Bile duct carcinoma: a late complication of congenital hepatic fibrosis: case report and review of literature. *Am J Gastroenterol.* 1980; **73**: 113–19.
- Lipsett PA, Pitt HA, Colombani PM, Boitnott JK, Cameron JL. Choledochal cyst disease: a changing pattern of presentation. *Ann Surg* 1994; **220**: 644–52.
- Ohtsuka T, Inoue K, Ohuchida J, et al. Carcinoma arising in choledochocoele. *Endoscopy* 2001; **33**: 614–19.
- van Mil SW, Klomp LW, Bull LN, Houwen RH. FIC1 disease: a spectrum of intrahepatic cholestatic disorders. *Semin Liver Dis* 2001; **21**: 535–44.
- Jacquemin E. Role of multidrug resistance 3 deficiency in pediatric and adult liver disease: one gene for three diseases. *Semin Liver Dis* 2001; **21**: 551–62.
- Thompson R, Strautnieks S. BSEP: function and role in progressive familial intrahepatic cholestasis. *Semin Liver Dis.* 2001; **21**: 545–50.
- Meier Y, Stieger B, Moore L, et al. Hepatocellular malignancy in ABCB11/BStP disease (progressive familial intrahepatic cholestasis, type 2): four patients. *Hepatology* 2004; **40** (suppl 1): 471A.
- Kubo S, Kinoshita H, Hirohashi K, Hamba H. Hepatolithiasis associated with cholangiocarcinoma. *World J Surg* 1995; **19**: 637–41.
- Chen MF. Peripheral cholangiocarcinoma (cholangiocellular carcinoma): clinical features, diagnosis and treatment. *J Gastroenterol Hepatol* 1999; **14**: 1144–49.
- Okuda K, Nakanuma Y, Miyazaki M. Cholangiocarcinoma: recent progress. Part 1: epidemiology and etiology. *J Gastroenterol Hepatol* 2002; **17**: 1049–55.
- Khan SA, Carmichael PL, Taylor-Robinson SD, Habib N, Thomas HC. DNA adducts, detected by <sup>32</sup>P postlabelling, in human cholangiocarcinoma. *Gut* 2003; **52**: 586–91.
- Sahani D, Prasad SR, Tannabe KK, Hahn PF, Mueller PR, Saini S. Thorotrast-induced cholangiocarcinoma: case report. *Abdom Imaging* 2003; **28**: 72–74.
- Hardell L, Bengtsson NO, Jonsson U, Eriksson S, Larsson LG. Aetiological aspects on primary liver cancer with special regard to alcohol, organic solvents and acute intermittent porphyria: an epidemiological investigation. *Br J Cancer* 1984; **50**: 389–97.
- Sorensen HT, Friis S, Olsen JH, et al. Risk of liver and other types of cancer in patients with cirrhosis: a nationwide cohort study in Denmark. *Hepatology* 1998; **28**: 921–25.
- Shin HR, Lee CU, Park HJ, et al. Hepatitis B and C virus, *Clonorchis sinensis* for the risk of liver cancer: a case-control study in Pusan, Korea. *Int J Epidemiol* 1996; **25**: 933–40.
- Donato F, Gelatti U, Tagger A, et al. Intrahepatic cholangiocarcinoma and hepatitis C and B virus infection, alcohol intake, and hepatolithiasis: a case-control study in Italy. *Cancer Causes Control* 2001; **12**: 959–64.
- Kobayashi M, Ikeda K, Saitoh S, et al. Incidence of primary cholangiocellular carcinoma of the liver in Japanese patients with hepatitis C virus-related cirrhosis. *Cancer* 2000; **88**: 2471–77.
- Yin F, Chen B. Detection of hepatitis C virus RNA sequences in hepatic portal cholangiocarcinoma tissue by reverse transcription polymerase chain reaction. *Chin Med J (Engl)* 1998; **111**: 1068–70.
- Berthiaume EP, Wands J. The molecular pathogenesis of cholangiocarcinoma. *Semin Liver Dis* 2004; **24**: 127–37.
- Nehls O, Gregor M, Klump B. Serum and bile markers for cholangiocarcinoma. *Semin Liver Dis* 2004; **24**: 139–54.
- Isa T, Tomita S, Nakachi A, et al. Analysis of microsatellite instability, K-ras gene mutation and p53 protein overexpression in intrahepatic cholangiocarcinoma. *Hepatogastroenterol* 2002; **49**: 604–08.
- Wang Y, Yamaguchi Y, Watanabe H, Ohtsubo K, Wakabayashi T, Sawabu N. Usefulness of p53 gene mutations in the supernatant of bile for diagnosis of biliary tract carcinoma: comparison with K-ras mutation. *J Gastroenterol* 2002; **37**: 831–39.
- Itoi T, Takei K, Shinohara Y, et al. K-ras codon 12 and p53 mutations in biopsy specimens and bile from biliary tract cancers. *Pathol Int* 1999; **49**: 30–37.

- 49 Aishima SI, Taguchi KI, Sugimachi K, Shimada M, Sugimachi K, Tsuneyoshi M. *c-erbB-2* and *c-Met* expression relates to cholangiocarcinogenesis and progression of intrahepatic cholangiocarcinoma. *Histopathology* 2002; **40**: 269–78.
- 50 Harnois DM, Que FG, Celli A, LaRusso NF, Gores GJ. Bcl-2 is overexpressed and alters the threshold for apoptosis in a cholangiocarcinoma cell line. *Hepatology* 1997; **26**: 884–90.
- 51 Okaro A, Deery A, Hutchins R, Davidson BR. The expression of anti-apoptotic proteins (Bcl-2, Bcl-xl, Mcl-1) by benign, dysplastic and malignant biliary epithelium. *J Clin Pathol* 2001; **54**: 927–32.
- 52 Taniai M, Higuchi H, Burgart LJ, Gores GJ. p16<sup>INK4a</sup> promoter mutations are frequent in primary sclerosing cholangitis (PSC) and PSC-associated cholangiocarcinoma. *Gastroenterol* 2002; **123**: 1090–98.
- 53 van Leeuwen DJ, Reeders JW. Primary sclerosing cholangitis and cholangiocarcinoma as a diagnostic and therapeutic dilemma. *Ann Oncol* 1999; **10** (Suppl 4): 89–93.
- 54 Jarnagin WR, Shoup M. Surgical management of cholangiocarcinoma. *Semin Liver Dis* 2004; **24**: 189–99.
- 55 Anderson CD, Pinson CW, Berlin J, Chari RS. Diagnosis and treatment of cholangiocarcinoma. *Oncologist* 2004; **9**: 43–57.
- 56 Patel AH, Harnois DM, Klee GG, LaRusso NF, Gores GJ. The utility of CA 19-9 in the diagnoses of cholangiocarcinoma in patients without primary sclerosing cholangitis. *Am J Gastroenterol* 2000; **95**: 204–07.
- 57 Lamerz R. Role of tumour markers, cytogenetics. *Ann Oncol* 1999; **10** (suppl 4): 145–49.
- 58 Albert MB, Steinberg WM, Henry JP. Elevated serum levels of tumor marker CA19-9 in acute cholangitis. *Dig Dis Sci* 1988; **33**: 1223–25.
- 59 Siqueira E, Schoen RE, Silverman W, et al. Detecting cholangiocarcinoma in patients with primary sclerosing cholangitis. *Gastrointest Endosc* 2002; **56**: 40–47.
- 60 Ramage JK, Donaghy A, Farrant JM, Iorns R, Williams R. Serum tumor markers for the diagnosis of cholangiocarcinoma in primary sclerosing cholangitis. *Gastroenterol* 1995; **108**: 865–69.
- 61 Saini S. Imaging of the hepatobiliary tract. *N Engl J Med* 1997; **336**: 1889–94.
- 62 Valls C, Guma A, Puig I, et al. Intrahepatic peripheral cholangiocarcinoma: CT evaluation. *Abdom Imaging* 2000; **25**: 490–96.
- 63 Zhang Y, Uchida M, Abe T, Nishimura H, Hayabuchi N, Nakashima Y. Intrahepatic peripheral cholangiocarcinoma: comparison of dynamic CT and dynamic MRI. *J Comput Assist Tomogr* 1999; **23**: 670–77.
- 64 Yeh TS, Jan YY, Tseng JH, et al. Malignant perihilar biliary obstruction: magnetic resonance cholangiopancreatographic findings. *Am J Gastroenterol* 2000; **95**: 432–40.
- 65 Manfredi R, Barbaro B, Masselli G, Vecchioli A, Marano P. Magnetic resonance imaging of cholangiocarcinoma. *Semin Liver Dis* 2004; **24**: 155–64.
- 66 Manfredi R, Brizi MG, Masselli G, Vecchioli A, Marano P. [Malignant biliary hilar stenosis: MR cholangiography compared with direct cholangiography]. *Radiol Med (Torino)*. 2001; **102**: 48–54.
- 67 Zidi SH, Prat F, Le Guen O, Rondeau Y, Pelletier G. Performance characteristics of magnetic resonance cholangiography in the staging of malignant hilar strictures. *Gut* 2000; **46**: 103–06.
- 68 Baron TH, Harewood GC, Rumalla A, et al. A prospective comparison of digital image analysis and routine cytology for the identification of malignancy in biliary tract strictures. *Clin Gastroenterol Hepatol* 2004; **2**: 214–19.
- 69 Fritscher-Ravens A, Broering DC, Sriram PV, et al. EUS-guided fine-needle aspiration cytodiagnosis of hilar cholangiocarcinoma: a case series. *Gastrointest Endosc* 2000; **52**: 534–40.
- 70 Abu-Hamda EM, Baron TH. Endoscopic management of cholangiocarcinoma. *Semin Liver Dis* 2004; **24**: 165–75.
- 71 Anderson CD, Rice MH, Pinson CW, Chapman WC, Chari RS, Delbeke D. Fluorodeoxyglucose PET imaging in the evaluation of gallbladder carcinoma and cholangiocarcinoma. *J Gastrointest Surg* 2004; **8**: 90–97.
- 72 Kato T, Tsukamoto E, Kuge Y, et al. Clinical role of (18)F-FDG PET for initial staging of patients with extrahepatic bile duct cancer. *Eur J Nucl Med Mol Imaging* 2002; **29**: 1047–54.
- 73 Kim YJ, Yun M, Lee WJ, Kim KS, Lee JD. Usefulness of 18F-FDG PET in intrahepatic cholangiocarcinoma. *Eur J Nucl Med Mol Imaging* 2003; **30**: 1467–72.
- 74 Fritscher-Ravens A, Bohuslavizki KH, Broering DC, et al. FDG PET in the diagnosis of hilar cholangiocarcinoma. *Nucl Med Commun* 2001; **22**: 1277–85.
- 75 Bismuth H, Nakache R, Diamond T. Management strategies in resection for hilar cholangiocarcinoma. *Ann Surg* 1992; **215**: 31–38.
- 76 Burke EC, Jarnagin WR, Hochwald SN, Pisters PW, Fong Y, Blumgart LH. Hilar Cholangiocarcinoma: patterns of spread, the importance of hepatic resection for curative operation, and a presurgical clinical staging system. *Ann Surg* 1998; **228**: 385–94.
- 77 Jarnagin WR, Fong Y, DeMatteo RP, et al. Staging, resectability, and outcome in 225 patients with hilar cholangiocarcinoma. *Ann Surg* 2001; **234**: 507–17.
- 78 Ebata T, Nagino M, Kamiya J, Uesaka K, Nagasaka T, Nimura Y. Hepatectomy with portal vein resection for hilar cholangiocarcinoma: audit of 52 consecutive cases. *Ann Surg* 2003; **238**: 720–27.
- 79 Corvera CU, Weber SM, Jarnagin WR. Role of laparoscopy in the evaluation of biliary tract cancer. *Surg Oncol Clin N Am* 2002; **11**: 877–91.
- 80 Su CH, Tsay SH, Wu CC, et al. Factors influencing postoperative morbidity, mortality, and survival after resection for hilar cholangiocarcinoma. *Ann Surg* 1996; **223**: 384–94.
- 81 Cameron JL, Pitt HA, Zinner MJ, Kaufman SL, Coleman J. Management of proximal cholangiocarcinomas by surgical resection and radiotherapy. *Am J Surg* 1990; **159**: 91–97.
- 82 Nimura Y, Hayakawa N, Kamiya J, Kondo S, Shionoya S. Hepatic segmentectomy with caudate lobe resection for bile duct carcinoma of the hepatic hilus. *World J Surg* 1990; **14**: 535–43.
- 83 Nakeeb A, Tran KQ, Black MJ, et al. Improved survival in resected biliary malignancies. *Surgery* 2002; **132**: 555–63.
- 84 Nimura Y, Kamiya J, Kondo S, et al. Aggressive preoperative management and extended surgery for hilar cholangiocarcinoma: Nagoya experience. *J Hepatobiliary Pancreat Surg* 2000; **7**: 155–62.
- 85 Hadjis NS, Blenkharn JI, Alexander N, Benjamin IS, Blumgart LH. Outcome of radical surgery in hilar cholangiocarcinoma. *Surgery* 1990; **107**: 597–604.
- 86 Pichlmayr R, Weimann A, Klempnauer J, et al. Surgical treatment in proximal bile duct cancer: a single-center experience. *Ann Surg* 1996; **224**: 628–38.
- 87 Lillemoe KD, Cameron JL. Surgery for hilar cholangiocarcinoma: the Johns Hopkins approach. *J Hepatobiliary Pancreat Surg* 2000; **7**: 115–21.
- 88 Fong Y, Blumgart LH, Lin E, Fortner JG, Brennan MF. Outcome of treatment for distal bile duct cancer. *Br J Surg* 1996; **83**: 1712–15.
- 89 Wade TP, Prasad CN, Virgo KS, Johnson FE. Experience with distal bile duct cancers in U.S. Veterans Affairs hospitals: 1987-1991. *J Surg Oncol* 1997; **64**: 242–45.
- 90 Kitagawa Y, Nagino M, Kamiya J, et al. Lymph node metastasis from hilar cholangiocarcinoma: audit of 110 patients who underwent regional and para-aortic node dissection. *Ann Surg* 2001; **233**: 385–92.
- 91 Figueras J, Llado L, Valls C, et al. Changing strategies in diagnosis and management of hilar cholangiocarcinoma. *Liver Transpl* 2000; **6**: 786–94.
- 92 Hemming AW, Reed AI, Howard RJ, et al. Preoperative portal vein embolization for extended hepatectomy. *Ann Surg* 2003; **237**: 686–91.
- 93 Abdalla EK, Barnett CC, Doherty D, Curley SA, Vauthey JN. Extended hepatectomy in patients with hepatobiliary malignancies with and without preoperative portal vein embolization. *Arch Surg* 2002; **137**: 675–80.
- 94 Todoroki T, Ohara K, Kawamoto T, et al. Benefits of adjuvant radiotherapy after radical resection of locally advanced main hepatic duct carcinoma. *Int J Radiat Oncol Biol Phys* 2000; **46**: 581–87.
- 95 Gonzalez Gonzalez D, Gouma DJ, et al. Role of radiotherapy, in particular intraluminal brachytherapy, in the treatment of proximal bile duct carcinoma. *Ann Oncol* 1999; **10** (Suppl 4): 215–20.
- 96 Pitt HA, Nakeeb A, Abrams RA, et al. Perihilar cholangiocarcinoma: postoperative radiotherapy does not improve survival. *Ann Surg* 1995; **221**: 788–97.

- 97 Meyer CG, Penn I, James L. Liver transplantation for cholangiocarcinoma: results in 207 patients. *Transplantation* 2000; **69**: 1633–37.
- 98 Jeyarajah DR, Klintmalm GB. Is liver transplantation indicated for cholangiocarcinoma? *J Hepatobiliary Pancreat Surg* 1998; **5**: 48–51.
- 99 Heimbach JK, Gores GJ, Haddock MG, et al. Liver transplantation for unresectable perihilar cholangiocarcinoma. *Semin Liver Dis* 2004; **24**: 201–07.
- 100 Farley DR, Weaver AL, Nagorney DM. “Natural history” of unresected cholangiocarcinoma: patient outcome after noncurative intervention. *Mayo Clin Proc* 1995; **70**: 425–29.
- 101 Berr F. Photodynamic therapy for cholangiocarcinoma. *Semin Liver Dis* 2004; **24**: 177–87.
- 102 Chang WH, Kortan P, Haber GB. Outcome in patients with bifurcation tumors who undergo unilateral versus bilateral hepatic duct drainage. *Gastrointest Endosc* 1998; **47**: 354–62.
- 103 Chari RS, Anderson CA, Saverese DMF. Treatment of cholangiocarcinoma II. In: Rose BD, ed. Up To Date. Wellesley, MA: UpToDate, 2003.
- 104 Prat F, Chapat O, Ducot B, et al. Predictive factors for survival of patients with inoperable malignant distal biliary strictures: a practical management guideline. *Gut* 1998; **42**: 76–80.
- 105 Cheung KL, Lai EC. Endoscopic stenting for malignant biliary obstruction. *Arch Surg* 1995; **130**: 204–07.
- 106 Schima W, Prokesch R, Osterreicher C, et al. Biliary Wallstent endoprosthesis in malignant hilar obstruction: long-term results with regard to the type of obstruction. *Clin Radiol* 1997; **52**: 213–19.
- 107 Kaassis M, Boyer J, Dumas R, et al. Plastic or metal stents for malignant stricture of the common bile duct? Results of a randomized prospective study. *Gastrointest Endosc* 2003; **57**: 178–82.
- 108 Dowsett JF, Vaira D, Hatfield AR, et al. Endoscopic biliary therapy using the combined percutaneous and endoscopic technique. *Gastroenterol* 1989; **96**: 1180–86.
- 109 Deviere J, Baize M, de Toeuf J, Cremer M. Long-term follow-up of patients with hilar malignant stricture treated by endoscopic internal biliary drainage. *Gastrointest Endosc* 1988; **34**: 95–101.
- 110 De Palma GD, Galloro G, Siciliano S, Iovino P, Catanzano C. Unilateral versus bilateral endoscopic hepatic duct drainage in patients with malignant hilar biliary obstruction: results of a prospective, randomized, and controlled study. *Gastrointest Endosc* 2001; **53**: 547–53.
- 111 De Palma GD, Pezzullo A, Rega M, et al. Unilateral placement of metallic stents for malignant hilar obstruction: a prospective study. *Gastrointest Endosc* 2003; **58**: 50–53.
- 112 Freeman ML, Overby C. Selective MRCP and CT-targeted drainage of malignant hilar biliary obstruction with self-expanding metallic stents. *Gastrointest Endosc* 2003; **58**: 41–49.
- 113 Isayama H, Komatsu Y, Tsujino T, et al. A prospective randomised study of “covered” versus “uncovered” diamond stents for the management of distal malignant biliary obstruction. *Gut* 2004; **53**: 729–34.
- 114 Sung J. Commentary. *Nature Clin Prac, Gastro & Hep* 2004; **1**: 21.
- 115 Ohnishi H, Asada M, Shichijo Y, et al. External radiotherapy for biliary decompression of hilar cholangiocarcinoma. *Hepatogastroenterol* 1995; **42**: 265–68.
- 116 Gerhards MF, van Gulik TM, Gonzalez Gonzalez D, Rauws EA, Gouma DJ. Results of postoperative radiotherapy for resectable hilar cholangiocarcinoma. *World J Surg* 2003; **27**: 173–79.
- 117 Patt YZ, Hassan MM, Lozano RD, et al. Phase II trial of cisplatin, interferon alpha-2b, doxorubicin, and 5-fluorouracil for biliary tract cancer. *Clin Cancer Res* 2001; **7**: 3375–80.
- 118 Choi CW, Choi IK, Seo JH, et al. Effects of 5-fluorouracil and leucovorin in the treatment of pancreatic-biliary tract adenocarcinomas. *Am J Clin Oncol* 2000; **23**: 425–28.
- 119 Ducreux M, Rougier P, Fandi A, et al. Effective treatment of advanced biliary tract carcinoma using 5-fluorouracil continuous infusion with cisplatin. *Ann Oncol* 1998; **9**: 653–56.
- 120 Ellis PA, Norman A, Hill A, et al. Epirubicin, cisplatin and infusional 5-fluorouracil (5-FU) (ECF) in hepatobiliary tumours. *Eur J Cancer* 1995; **31A**: 1594–98.
- 121 Nehls O, Klump B, Arkenau HT, et al. Oxaliplatin, fluorouracil and leucovorin for advanced biliary system adenocarcinomas: a prospective phase II trial. *Br J Cancer* 2002; **87**: 702–04.
- 122 Gebbia V, Giuliani F, Maiello E, et al. Treatment of inoperable and/or metastatic biliary tree carcinomas with single-agent gemcitabine or in combination with levolefolinic acid and infusional fluorouracil: results of a multicenter phase II study. *J Clin Oncol* 2001; **19**: 4089–91.
- 123 Papakostas P, Kouroussis C, Androulakis N, et al. First-line chemotherapy with docetaxel for unresectable or metastatic carcinoma of the biliary tract: a multicentre phase II study. *Eur J Cancer* 2001; **37**: 1833–38.
- 124 Dowlati A, Posey J, Ramanathan RK. Multicenter phase II and pharmacokinetic study of rebeccamycin analogue in advanced biliary cancers. *Proc Am Soc Clin Oncol* 2003; **22**: 267a.
- 125 Thongprasert S, Napapan S, Charoentum C, Moonprakan S. Phase II study of gemcitabine and cisplatin as first-line chemotherapy in inoperable biliary tract carcinoma. *Ann Oncol* 2005; **16**: 279–81.
- 126 Knox JJ, Hedley D, Oza A, et al. Combining gemcitabine and capecitabine in patients with advanced biliary cancer: a phase II trial. *J Clin Oncol* 2005 **1**; **23**: 2332–38.
- 127 Ortner ME, Caca K, Berr F, et al. Successful photodynamic therapy for non-resectable cholangiocarcinoma: a randomized prospective study. *Gastroenterol* 2003; **125**: 1355–63.