

# Advancement sleeve flaps for treatment of severe perianal Crohn's disease

P. MARCHESA, T. L. HULL and V. W. FAZIO

Department of Colorectal Surgery, The Cleveland Clinic Foundation, 9500 Euclid Avenue, Cleveland, Ohio 44195, USA

Correspondence to: Dr T. L. Hull

**Background** Traditionally proctectomy has been the treatment for severe, complex fistula *in ano* from Crohn's disease. However, based on the success of rectal advancement flaps in Crohn's disease, circumferential transanal sleeve advancement flaps (TSAFs) were proposed for this subgroup of patients with severe fistula.

**Methods** From 1991 to 1995, 13 patients (12 women) with severe perianal Crohn's disease and multiple fistula tracts underwent a TSAF procedure. Data were collected retrospectively using a standard data sheet.

**Results** There were no postoperative deaths or major morbidity. One year after surgery, the fistula had healed in eight of 13 patients (with three requiring additional surgery before healing). Of patients in whom the procedure failed, three underwent proctectomy for progression of disease and the other two had recurrence of a rectovaginal fistula 6 and 8 months after surgery. Of six variables evaluated (previous procedure, steroid use, steroid dosage, associated Crohn's disease, associated procedures and diverting stoma), only associated procedures were significantly related to a successful outcome ( $P=0.008$ ).

**Conclusion** Some patients with severe perianal Crohn's fistula and a relatively normal rectum can be offered TSAFs. Even with successful outcome in eight of 13 patients, this may still be a viable option if the only alternative would be total proctocolectomy and a permanent stoma.

The management of perianal fistulas associated with Crohn's disease is often challenging and should be tailored to the specific patient. The surgical treatment of these perianal manifestations is based on the location and complexity of the fistula, the presence or absence of concomitant proctitis, sphincteric competence and the severity of accompanying anal canal disease<sup>1</sup>.

Patients with symptomatic low-lying simple fistulas involving minimum sphincter musculature without concomitant proctitis can be treated appropriately by fistulotomy<sup>2-4</sup>. Where faecal continence could be compromised by partial sphincter division in patients with trans-sphincteric or anovaginal fistulas, advancement of partial-thickness flaps has been proposed as the treatment of choice in selected patients with a normal rectum<sup>5,6</sup>. However, extensive ulceration or stricturing of the anal canal and transitional zone is a contraindication for the endoanal sliding advancement flap technique.

Definitive treatment of severe perianal Crohn's disease, including complex fistula *in ano* and rectovaginal and rectourethral fistula, has traditionally been proctectomy<sup>7-9</sup>. The technique of rectal sleeve advancement was described by Berman<sup>10</sup> in a woman with combined rectovaginal and cryptogenetic fistulas involving more than one-third of the anal circumference. Since 1991 the authors have used a similar technique for selected complex perianal fistulas resulting from Crohn's disease.

The purpose of this study was to examine the outcome after a transanal sleeve advancement flap (TSAF) procedure in a subgroup of patients with severe and symptomatic perianal Crohn's disease. The primary

endpoint was the success rate, which was defined as healing of the fistulas and ulcers 1 year following surgery.

## Patients and methods

Between August 1991 and May 1995, 13 patients with severe complex perianal Crohn's disease were treated surgically by one surgeon (V.W.F.) by TSAFs. TSAF repair was proposed as an alternative to proctectomy in patients with perianal Crohn's disease associated with serious and disabling symptoms, such as drainage of malodorous secretions, perianal discomfort and pain, difficulty with hygiene, and dispareunia lasting at least 6 months. Patients were considered eligible for TSAFs if they had multiple fistulous tracts (including extension to the vagina and/or urethra) and histopathologically proven Crohn's cavitating ulcerations of the anal canal with or without anal canal stenosis. Preoperative proctoscopy was performed in all patients to evaluate the rectum. Patients were not candidates for TSAFs if they had moderate to severe proctitis, rectal stricture or active sepsis. However, the procedure was considered after adequate control of sepsis with abscess drainage with or without seton placement and with or without antibiotic therapy.

A retrospective review of the medical records was conducted using a standard data sheet. Follow-up information was obtained by office visits or by telephone contact. Data were collected for parameters that might influence the success rate: previous surgical treatment for perianal Crohn's disease; steroid use; steroid dosage; presence, activity and location of Crohn's disease proximal to the anorectum; surgical procedures performed to treat proximal concomitant Crohn's disease at the same setting as TSAFs; and use of a diverting stoma and outcome.

Follow-up for evaluation of the success rate was at least 12 months starting from the TSAF procedure or stoma closure (when protective ostomy was used). The outcome was considered successful when healing of the fistula or ulcer with symptom reduction was observed 1 year following surgery independently of the need for additional minor surgical procedures. The  $\chi^2$  test

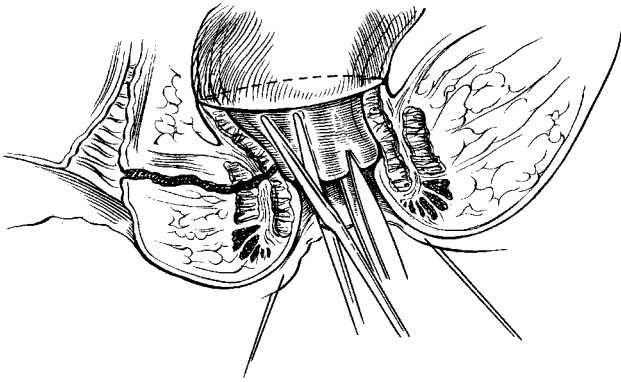


Fig. 1 A full-thickness sleeve flap is raised in a cephalad direction resulting in exposed denuded fibres of internal sphincter. Dissection is carried into the supralevator space until sufficient mobility is obtained

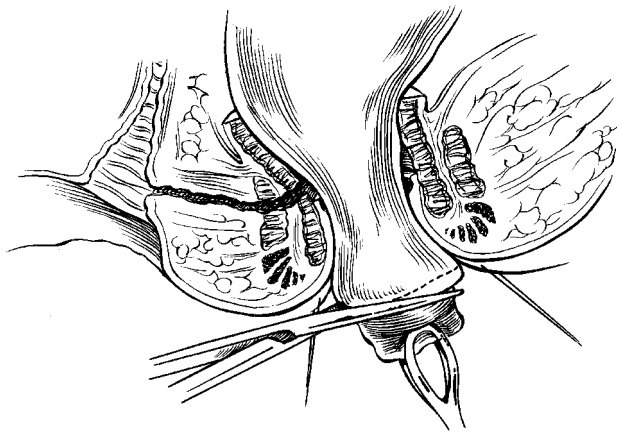


Fig. 2 After the internal opening of the fistula tract has been cored out and closed, the distal cylinder of diseased tissue is trimmed from the flap. The edge of the flap can then be sutured to the neodentate line

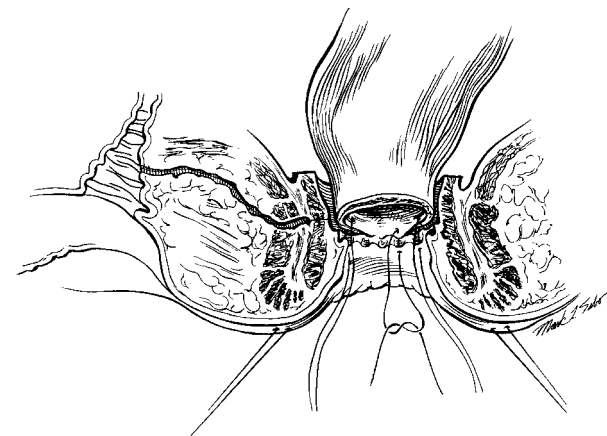


Fig. 3 The distal edge of the flap is sutured to the ridge of the new dentate line using interrupted 3/0 polyglactin sutures. A reinforcing layer of continuous 3/0 polyglactin suture is then added (not shown in this figure)

was used to evaluate the effect of a number of variables on the success rate.

#### Surgical technique

After full bowel preparation and induction of anaesthesia the patient is positioned in the prone jack-knife position. Polyglycolic acid sutures (no. 1) are applied at the anal verge as everting sutures to allow increased visualization of the anorectum. Adrenaline 1 : 200 000 is injected circumferentially into the anal canal and lower rectum. Using diathermy or scissors, a 90–100 per cent circumferential incision is made at or just below the dentate line, distal to the fistula opening or anal canal ulceration. A full-thickness (mucosa, submucosa and few fibres of internal sphincter) 'sleeve' flap is raised in a cephalad direction resulting in exposed denuded fibres of the internal sphincter. A few fibres of internal muscle are included in the sleeve of tissue owing to the inflammation from the fistula process. As much internal sphincter is preserved as possible. The dissection is carried into the supralevator space until sufficient mobility is achieved to permit the full thickness of rectum to be advanced caudally into the anal canal without tension (Fig. 1).

The fistula tracts are cored out and the anal opening is closed in layers with absorbable suture (2/0 polyglactin on a UR 6 needle) leaving the other side of the fistula open to allow drainage. The cylinder of distal diseased tissue is trimmed from the flap (Fig. 2). The flap is then supported with radially placed 2/0 polyglactin sutures from the undersurface of the flap to adjacent tissue (internal sphincter) to relieve tension and prevent retraction. The distal edge of the flap is sutured to the ridge of the new dentate line using interrupted 3/0 polyglactin sutures followed by a continuous reinforcing layer of 3/0 polyglactin sutures (Fig. 3).

In certain cases mobilization may be carried to the peritoneal reflection anteriorly to create more rectal wall mobility. Before operation the patient is warned about the possible need for diversion and for mobilization of the rectum via a transabdominal approach (so far the latter has not been necessary).

#### Results

There were 12 women and one man in the group. Median age at the time of surgery was 40 (range 25–60) years. All patients had complex severe perianal Crohn's disease including recurrent rectovaginal fistulas (four patients), associated rectovaginal and multiple perianal fistulas (seven patients) with anal stricture in two cases, associated rectourethral and perianal fistulas (one) and recurrent multiple anal canal ulceration (one). Symptoms related to perianal disease had been present for a median of 36 (range 10–180) months before operation. All patients but one had undergone previous surgery for perianal disease: transanal rectal advancement flap (five patients), debridement and draining seton placement (five) and fistulectomy (two).

At the time of the TSAF procedure ten patients were taking steroids (associated with azathioprine in two), one patient was taking 6-mercaptopurine and two patients were receiving no medication. Of the patients treated with steroids, four were receiving prednisone 10 mg daily and six 20 mg daily. The rectum was relatively spared in all patients; there were endoscopic signs of mucosal erythema in only three patients. Perianal disease was associated with proximal Crohn's disease in 12 patients (six with ileal and six with colonic disease). Six patients had a concomitant bowel resection (carried out at the same setting as the TSAF procedure): subtotal colectomy plus ileorectal anastomosis (one patient), ileotransverse resection and neoanastomosis (two), ileorectal resection

Table 1 Analysis of improvement (success rate)

Variable/Response	Improvement		P*
	Total	No.	
Previous procedure			
Yes	12	7	0.41
No	1	1	
Drainage	8	5	0.65
Repair	4	2	
None	1	1	
Steroid use			
Yes	10	7	0.25
No	3	1	
Steroid dosage			
10	4	4	0.09
20	6	3	
Associated Crohn's disease			
Yes	12	8	0.19
No	1	0	
Small bowel	6	4	0.42
Colon	6	4	
None	1	0	
Associated procedures			
Yes	6	6	0.008†
No	7	2	
Diverting stoma			
Yes	8	6	0.21
No	5	2	

\* $\chi^2$  test; †significant ( $P < 0.05$ )

and neostomosis (two), and right hemicolectomy with ileal stricturoplasty (one). All six patients who underwent a concomitant surgical procedure also had a covering stoma.

A TSAF procedure was performed with concomitant faecal diversion in eight patients. Five of these eight patients had the ostomy closed within a median of 5 (range 3–9) months. All five patients had a concomitant bowel resection. The sixth patient who had faecal diversion and a concomitant abdominal procedure for Crohn's disease at the time of the TSAF operation still had a protective stoma at the end of the study period because of faecal incontinence. This patient's continence failed to improve despite fistulectomy and sphincter repair performed 5 months after the TSAF procedure for recurrent fistulas. However, by the end of the study this patient did not show any fistula recurrence and no recurrences were observed during a total of 42 months after TSAF repair.

Two patients who had faecal diversion did not have a concomitant abdominal procedure. They underwent proctectomy for progressive perianal disease 5 and 15 months following a TSAF procedure.

There was no postoperative death or major morbidity. Median hospital stay for the whole group of patients was 7 (range 6–20) days. Median follow-up was 15 (range 12–48) months. Eight of the 13 patients had healing of the fistulas and ulcers 1 year following surgery with an overall success rate of 61 per cent. All patients with a successful outcome had a significant improvement in symptoms related to perianal disease; in particular, discharge of purulent secretions was resolved totally.

Of patients with a successful outcome three required additional surgery after the TSAF procedure: transanal

rectal advancement flap for persistent sinus (two patients) and fistulectomy plus sphincter repair for recurrent fistulas associated with faecal incontinence (one). Of patients in whom the procedure failed, three underwent proctectomy because of recurrence and secondary progression of the perianal disease 5, 12 and 15 months following advancement flap surgery. The other two patients had recurrence of a rectovaginal fistula 6 and 8 months after surgery (the fistulas were still present at the last follow-up visit).

Success rate was then related to six primary variables of interest (Table 1). The success rate was significantly higher only for patients who underwent concomitant bowel resection (six of six versus two of seven;  $P = 0.008$ ). Although some of the results may appear to be clinically significant (absence of previous surgical perianal procedures and use of diverting stoma) they are not statistically significant because of the small sample size.

## Discussion

Advancement flap repair of anal fistulas, with and without Crohn's disease, has been reported previously<sup>5,6</sup>. The flap technique has been demonstrated to be effective in the treatment of complex rectovaginal and perianal fistula because it incorporates a layer of intact healthy tissue into the high-pressure side of a high–low pressure shunt at the level of the anal canal<sup>11</sup>. The limitations of the 'conventional' flap include a variety of conditions found in perianal Crohn's disease such as extensive, circumferential ulceration and inflammation of the anal canal up to the anorectal ring. Such circumstances usually preclude any effective definitive treatment that leaves the patient with a functioning anal canal.

In recent years, encouraging results after local anorectal operations in patients with Crohn's disease have led surgeons to attempt more aggressive surgical management of Crohn's perianal disease<sup>12,13</sup>. As there is no cure for Crohn's disease an important goal of therapy should be symptom relief. The surgical strategy at this institution has therefore been to offer patients a chance of repair even in the presence of traditionally adverse features. TSAF repair has been offered as an alternative to proctectomy to patients with severely symptomatic perianal Crohn's disease that is causing overwhelming mental anguish.

The sleeve technique described here includes resection of a cylinder of diseased anal canal, with mobilization of the low rectum and advancement to the dentate line for a neodentate anastomosis. Such mobilization can usually be done with little or no tension, and also allows for apposition of two ends that contain little or no active inflammation.

Selection of patients is important to reduce the risk of a non-healing wound and worsening perianal disease. Acute perianal sepsis needs to be resolved before the flap procedure. The rectum should be relatively free from Crohn's disease at the time of surgery. However, the presence of an old erythema did not affect the final outcome in the present series. Treatment with steroids seems to be associated with better outcome, possibly because of remission of Crohn's disease elsewhere, as demonstrated in previous reports with flap procedures<sup>6</sup>. Patients needing a lower steroid dosage (10 mg) tended to have a higher success rate perhaps because of a potentially less aggressive inflammatory process. The importance of optimal control of proximal Crohn's disease

for the success of this operation is implied from the successful outcome in all six patients who underwent proximal bowel resection in association with the advancement flap procedure (although one patient still had a stoma for faecal incontinence at the end of the study). Although use of a stoma is controversial, this observation supports the notion that proximal disease control will improve more distal disease<sup>14,15</sup>.

A critical component of the selection process is the careful preoperative evaluation of local conditions. The examination includes precise anatomical definition and characterization of the fistulas, assessment of normal distensibility of the rectum, and demonstration of adequate mobility and pliability of the rectal wall by grasping the wall itself with a Babcock clamp. If necessary this examination should be performed under anaesthesia in the operating room.

Success after TSAF surgery is more likely when principles valid for the flap repair technique are adhered to closely<sup>5</sup>: careful haemostasis aided by adrenaline infiltration, adequate blood supply to the distal end of the 'sleeve' flap, avoidance of excessive tension on the invaginated rectum and complete debridement or excision of the fistula tract followed by layered closure of the internal opening. The role of faecal diversion is still controversial. Six of eight patients with a diverting stoma had a successful outcome compared with two of five patients treated without diversion. There were no set criteria for stoma construction in this series of patients. The use of a stoma depended on the surgeon's satisfaction with the technical conduct of the operation. However, considering the complexity of TSAFs, especially in inexperienced hands, use of stoma protection as a standard part of the procedure is recommended.

TSAFs allow additional perianal procedures to be performed. Two patients in this series required conventional rectal mucosal advancement flaps for a persistent sinus at the level of the anorectum. Another patient underwent fistulectomy and sphincter repair because of a persistent trans-sphincteric fistula associated with faecal incontinence. All three patients had a favourable outcome after these additional procedures, resulting in ultimate success following TSAF surgery.

The feasibility of conservative treatment of severe complex perianal Crohn's disease has been demonstrated. The TSAF procedure is associated with a relatively short hospital stay and an acceptable postoperative outcome. Although the study group was small and the follow-up period relatively short, the healing rate of 60 per cent is a quite impressive, especially in view of the significant reduction in symptoms.

In conclusion, TSAF can be offered as an effective surgical option in selected cases of severe Crohn's perianal disease associated with a normal rectum,

especially if the only alternatives would be total proctocolectomy or permanent faecal diversion. The significant number (five of 13) of patients who failed to improve may be a reflection of the aggressiveness of the perianal disease. In this subgroup of patients radical treatment is always possible. Careful preoperative selection and meticulous surgical technique are required to achieve success.

## References

- 1 Bayer I, Gordon PH. Selected operative management of fistula-in-ano in Crohn's disease. *Dis Colon Rectum* 1994; 37: 760-5.
- 2 Fry RD, Shemesh El Kodner IJ, Timmcke A. Techniques and results in the management of anal and perianal Crohn's disease. *Surg Gynecol Obstet* 1989; 168: 42-8.
- 3 Sohn N, Korelitz BI, Weinstein MA. Anorectal Crohn's disease: definitive surgery for fistulas and recurrent abscesses. *Am J Surg* 1980; 139: 394-7.
- 4 Levien DH, Surrell J, Mazier WP. Surgical treatment of anorectal fistula in patients with Crohn's disease. *Surg Gynecol Obstet* 1989; 169: 133-6.
- 5 Jones IT, Fazio VW, Jagelman DG. The use of transanal rectal advancement flaps in the management of fistulas involving the anorectum. *Dis Colon Rectum* 1987; 30: 919-23.
- 6 Makowiec F, Jehle EC, Becker HD, Starlinger M. Clinical course after transanal advancement flap repair of perianal fistula in patients with Crohn's disease. *Br J Surg* 1995; 82: 603-6.
- 7 Goligher JC. Rectovaginal fistula and irradiation proctitis and enteritis. In: Goligher JC, Dothie BL, Nixon HH, eds. *Surgery of the Anus, Colon, and Rectum*. Springfield, Illinois: Charles C Thomas, 1975: 205-55.
- 8 Faulconer HT, Muldoon JP. Rectovaginal fistula in patients with colitis: review and report of a case. *Dis Colon Rectum* 1975; 18: 413-15.
- 9 Radcliffe AG, Ritchie JK, Hawley PR, Lennard-Jones JE, Northover JMA. Anovaginal and rectovaginal fistulas in Crohn's disease. *Dis Colon Rectum* 1988; 31: 94-9.
- 10 Berman IR. Sleeve advancement anorectoplasty for complicated anorectal/vaginal fistula. *Dis Colon Rectum* 1991; 34: 1032-7.
- 11 Greenwald JC, Hoexter B. Repair of rectovaginal fistulas. *Surg Gynecol Obstet* 1978; 146: 443-5.
- 12 Williamson PR, Hellinger MD, Larach SW, Ferrara A. Twenty-year review of the surgical management of perianal Crohn's disease. *Dis Colon Rectum* 1995; 38: 389-92.
- 13 Sangwan YP, Schoetz DJ Jr, Murray JJ, Roberts PL, Coller JA. Perianal Crohn's disease. Results of local surgical treatment. *Dis Colon Rectum* 1996; 39: 529-35.
- 14 Hellers G, Bergstrand O, Ewerth S, Holmstrom B. Occurrence and outcome after primary treatment of anal fistulae in Crohn's disease. *Gut* 1980; 21: 525-7.
- 15 Heuman R, Bolin T, Sjobdahl R, Tagesson C. The incidence and course of perianal complications and arthralgia after intestinal resection with restoration of continuity for Crohn's disease. *Br J Surg* 1981; 68: 528-30.