

Simplifying Minimally Invasive Transhiatal Esophagectomy With the Inversion Approach

Lessons Learned From the First 20 Cases

Blair A. Jobe, MD; Charles Y. Kim, MD; Renee C. Minjarez, MD; Robert O'Rourke, MD; Eugene Y. Chang, MD; John G. Hunter, MD

Hypothesis: The laparoscopic transhiatal esophagectomy can be simplified and performed safely and effectively by using a novel esophageal inversion technique.

Design: Case series describing technique, initial experience, and learning curve with laparoscopic inversion esophagectomy.

Setting: Tertiary care university hospital and veteran's hospital.

Patients: Twenty consecutive patients with high-grade dysplasia (n=16) and esophageal adenocarcinoma (n=4).

Intervention: Laparoscopic inversion esophagectomy, a totally laparoscopic approach to transhiatal esophagectomy that incorporates distal to proximal inversion to improve mediastinal exposure and ease of dissection.

Main Outcome Measures: Perioperative end points and complications, compared between the first and second groups of 10 patients.

Results: There were 19 men and 1 woman. Median operative time was 448 minutes. Median blood loss was 175 cm³. Median intensive care unit stay was 4 days, and median total hospital stay was 9 days. Overall anastomotic leak rate was 20%. Five patients developed an anastomotic stricture, all successfully managed with endoscopic dilation. There were 2 recurrent laryngeal nerve injuries, which resolved. There was no intraoperative or 30-day mortality. Between the first 10 consecutive cases and last 10 procedures, the incidence of anastomotic leak and stricture formation decreased from 30% to 10% and 40% to 10%, respectively. During this period, the number of lymph nodes harvested increased 9-fold, and duration of intensive care unit stay decreased from 8.00 to 2.50 days.

Conclusions: Laparoscopic inversion esophagectomy is a safe procedure. The learning curve for the inversion approach is approximately 10 operations in the hands of esophageal surgeons with advanced laparoscopic expertise.

Arch Surg. 2006;141:857-866

Author Affiliations:

Department of Surgery, Oregon Health & Science University (Drs Jobe, Kim, Minjarez, O'Rourke, Chang, and Hunter), and Surgical Services, Portland VA Medical Center (Dr Jobe), Portland.

SINCE FIRST DESCRIBED IN 1995,¹ interest has developed in minimally invasive esophagectomy for both benign and malignant disease. However, as currently performed, minimally invasive esophagectomy and its variants are perceived to be very difficult and have not provided the improvements in morbidity rates associated with some of its sibling operations, such as laparoscopic Nissen fundoplication, and giant paraesophageal hernia repair. In a recent survey of esophageal cancer treatment practices, one third of surgeons who had performed minimally invasive esophagectomy had permanently abandoned the approach because of technical difficulty, increased patient morbidity, or prolonged operative times.² The perception among surgeons is that the widespread adoption of minimally in-

sive esophagectomy is hampered in the face of a difficult procedural learning curve coupled with a limited number of cases for training and lack of evidence demonstrating a clear benefit. As such, minimally invasive esophagectomy remains confined to centers of specialized expertise.^{1,3,4}

Luketich and colleagues^{3,4} have established the 2-cavity esophageal mobilization with cervical anastomosis as their standard in minimally invasive approaches to esophagectomy in patients with cancer or high-grade dysplasia. In the largest reported series to date, this group demonstrated an operative mortality rate well below the national standard, short intensive care unit stay, low anastomotic leak rate, and return of quality of life to population norms. Perhaps, most importantly, the stage-specific survival rates were equivalent to those reported in open series at 1.5

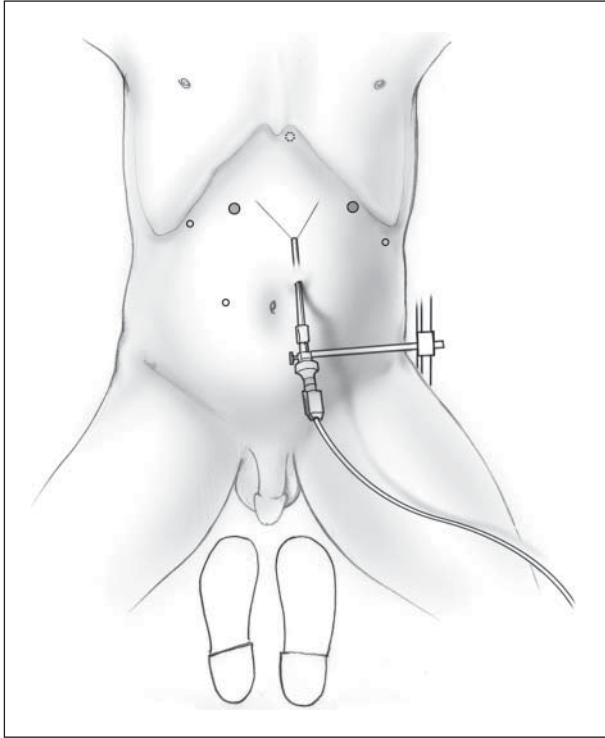


Figure 1. Port placement. Note the surgeon's 12-mm left-hand port, which allows passage of the endostapler. Illustration by Corinne Sandone, Johns Hopkins University. Reprinted with permission.

years' follow-up. However, these results are from a single institution, and until a multicenter trial is completed, one cannot generalize these results to the wider community of esophageal surgeons. In contrast, the laparoscopic transhiatal approach to esophagectomy has not experienced the same degree of success and is reported in only several small case series.⁵⁻⁸ The primary reason this approach has not been widely adopted is related to the technical complexity of the posterior mediastinal dissection and the limited work space adjacent to vital structures.

The laparoscopic inversion esophagectomy (LIE) attempts to eliminate some of the technical obstacles inherent in the transhiatal approach by simplifying the mediastinal dissection and enhancing safety. The LIE is a modification⁹ based on the open inversion technique used for vagal preservation as described by Akiyama and colleagues.¹⁰ Laparoscopic inversion esophagectomy is a totally laparoscopic approach that uses distal-to-proximal inversion of the esophagus assisted by a vein stripper that has been passed through a cervical esophagotomy. The advantages of this approach are inherent in the dramatic increase in mediastinal work space and improved endoscopic visualization as the esophagus is rolled outside-in toward the neck incision. This modification allows the surgeon to dissect the esophagus and surrounding structures "end-on" and eliminates the need for lateral esophageal retraction in order to provide counter-tension during mobilization. Additionally, the inversion accentuates the points of esophageal mediastinal fixation allowing for precision in dissection. This study describes the technique for totally LIE and reviews our initial experience in the first 20 consecutive cases.

At Oregon Health & Science University and the Portland VA Medical Center, 20 patients underwent LIE between September 2002 and May 2005. This series includes our entire experience with LIE during this time. Demographics, symptoms, lifestyle variables (alcohol consumption and tobacco use), medical history, and clinical staging were collected prospectively and entered into a database approved by the institutional review boards of both institutions. Perioperative and postoperative data and pathologic staging were collected retrospectively from medical record review. The following end points were collected for each patient: age, sex, body mass index (calculated as weight in kilograms divided by height in meters squared), clinical stage, use of induction therapy, anastomosis technique, conversion rate, operative time, inversion technique (vein stripper vs nasogastric tube), lymph node yield, blood loss, placement of jejunostomy feeding tube, complications, length of intensive care unit stay, and length of total hospital stay. Late follow-up was at 17 months (range, 1-38 months). The outcomes of the initial 10 consecutive cases (group 1) were compared with the final 10 cases (group 2). Procedural modifications throughout our learning curve were examined.

INDICATIONS FOR INVERSION ESOPHAGECTOMY

The LIE is used with benign, end-stage esophageal conditions; high-grade dysplasia; and select patients with esophageal cancer that does not bridge the esophagogastric junction. A combined laparoscopic/thoracoscopic approach is reserved for patients with advanced locoregional disease where inversion may be difficult, patients with malignancies of the proximal esophagus, or when resectability is in question. Prior pleural space infection and history of mediastinitis represent contraindications to LIE.

TECHNIQUE FOR LIE

Patient Positioning

The patient is placed supine and in a split-legged position with a small towel roll behind the patient's scapulae. The surgeon stands between the legs. The first assistant stands at the patient's left and the second assistant, at the patient's right. The abdomen, chest, and left side of the neck are prepped in the same field.

Port Placement

A 6-port technique is used—three 5-mm, one 10-mm, and two 12-mm ports (**Figure 1**). The primary site of access is approximately 15 cm below the left costal margin, 2 to 3 cm to the left of midline. A 45° laparoscope is introduced through this port, and intra-abdominal exploration is performed. The second port for the surgeon's right-hand instruments is placed 12 cm from the tip of the xiphoid process, 2 cm below the left costal margin. The third port is placed within the left anterior axillary line along the costal margin. This 5-mm trocar serves as the primary port site for the first assistant. The fourth port is created immediately to the left of the xiphoid process for placement of the Nathanson liver retractor (Cook Surgical, Bloomington, Ind) to expose the hiatal opening and gastrohepatic omentum. The fifth port is placed inferior to the right costal margin immediately to the right of the falciform ligament. The trocar should enter with a slightly upward trajectory, immediately inferior to the left lat-

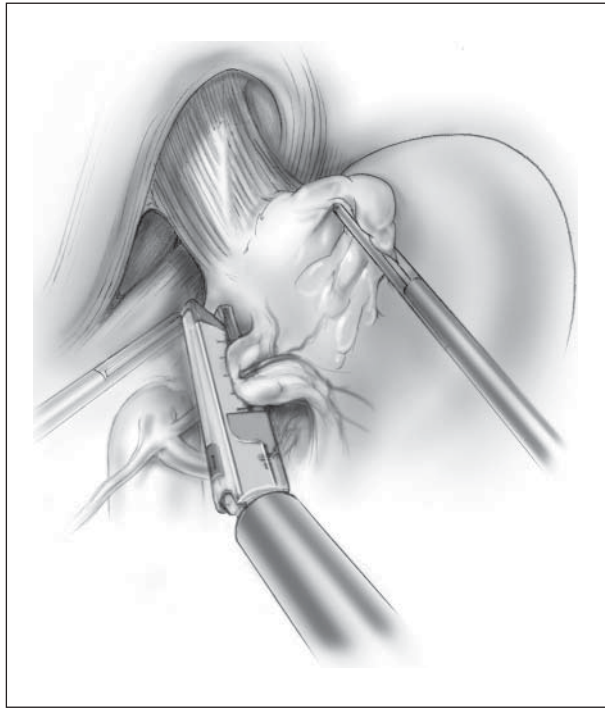


Figure 2. Division of the left gastric artery. The division is performed as low to the celiac axis as possible to maximize the number of nodes harvested. Retracting the esophagogastric junction laterally and anteriorly straightens the course of the left gastric vessels, facilitating division by a vascular stapler introduced through the 12-mm port. The position of the hepatic artery may be determined by noting its pulsation. Illustration by Corinne Sandone, Johns Hopkins University. Reprinted with permission.

eral segment of the liver. This 12-mm port provides access for the surgeon's left-hand instruments and for the endoscopic stapling device. The sixth port is placed in the patient's right midabdomen and is tailored based on internal anatomy. This 5-mm port enables the second assistant to elevate the gastric antrum during mobilization of the greater curvature.

Hiatal Dissection and Division of Left Gastric Vessels

The gastrohepatic omentum is opened with a harmonic scalpel. The phrenoesophageal membrane is placed on tension and opened from the apex of the crural diaphragm until the left crural bundle is easily identified. The esophagus and angle of His are dissected away from the left crus and diaphragm. The phrenoesophageal membrane is opened along the right crus, and the fibroareolar space is developed. This dissection is carried from the apex of the crural arch anteriorly to the union of the right and left crural pillars. All lymphatics posterior to the esophagus are maintained en bloc with the esophagogastric junction. The peritoneum overlying the base of the left gastric artery is opened with the harmonic shears, and all lymphatic tissue is elevated in this region. The left gastric artery is divided at its origin (**Figure 2**).

Division of the Short Gastric Vessels and Pancreaticogastric Fold

The short gastric vessels are divided. The posterior aspect of the stomach is mobilized as the union of the left and right gastroepiploic vessels is preserved. The posterior pancreaticogastric fold and accompanying posterior gastric artery are divided (**Figure 3**). Filmy bands from the posterior stomach to the anterior surface of the pancreas are divided. This dissec-

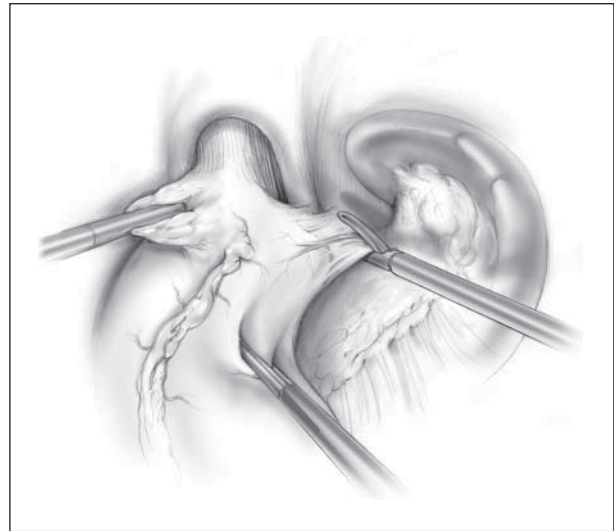


Figure 3. Division of the posterior gastric artery. After division of the short gastric arteries, the posterior stomach is exposed. The posterior gastric artery, which originates along the splenic artery, is divided with a harmonic scalpel. The pancreatic bed is seen inferiorly. The stomach is retracted inferiorly by the assistants. Illustration by Corinne Sandone, Johns Hopkins University. Reprinted with permission.

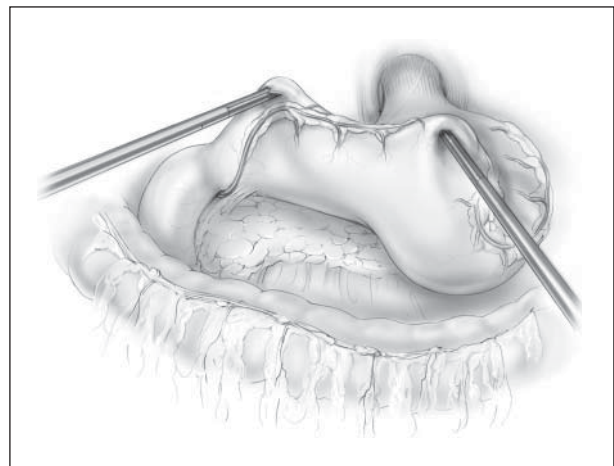


Figure 4. View of the posterior stomach. The gastrocolic ligament has been divided, preserving the right gastroepiploic artery, which will ultimately supply the gastric conduit. The position of the right gastroepiploic artery is illustrated, although it is not necessary or desirable to dissect it from the surrounding tissue. Illustration by Corinne Sandone, Johns Hopkins University. Reprinted with permission.

tion is carried proximally. In the case of esophagectomy for malignancy, all lymphatic tissue in this region should be maintained with the specimen. The esophagogastric junction is completely mobilized away from the left crus. Continuity is established with the right-sided dissection, and the posterior esophageal window is created.

Greater Curvature and Posterior Gastric Mobilization

The entire gastrocolic ligament is divided, and the dissection is carried distally to continue mobilizing the posterior gastric wall away from the anterior surface of the pancreas (**Figure 4**). The posterior gastric and duodenal dissection is completed at the point when the pulsations of the gastric duodenal artery are visualized. A Kocher maneuver is performed. The retro-

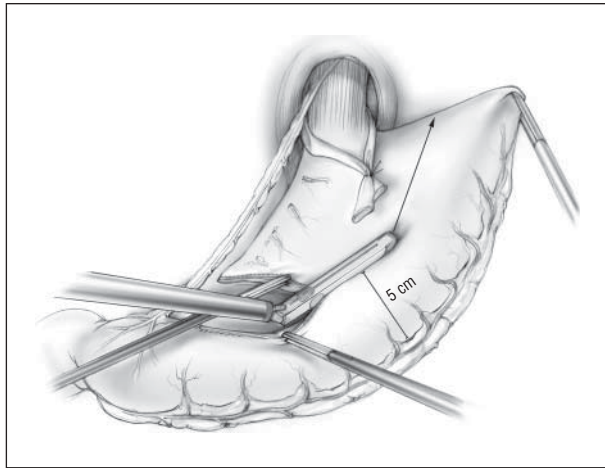


Figure 5. Creation of the neoesophagus with vagal preservation. Stapling is performed through the surgeon's 12-mm port, beginning at approximately 6 cm from the pylorus on the lesser curvature, proceeding cephalad along the greater curvature, ultimately resulting in a 5-cm-wide gastric tube. The assistants play a key role in aligning the stomach in a plane, which facilitates the creation of a gastric conduit without "barber poling." Illustration by Corinne Sandone, Johns Hopkins University. Reprinted with permission.

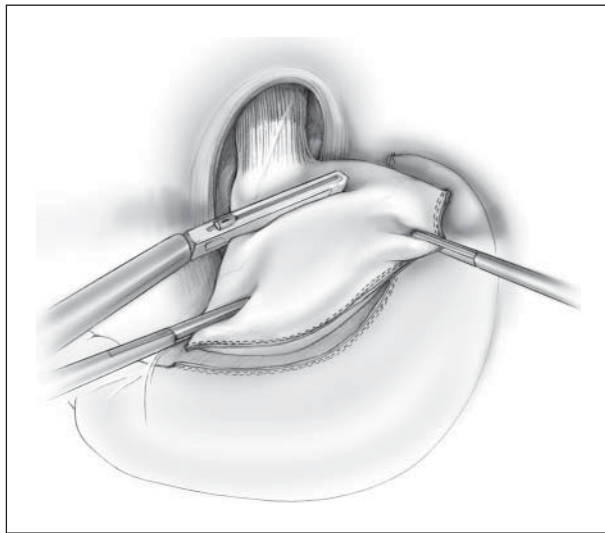


Figure 6. Preparation for inversion. Intraoperative endoscopy is used to identify the esophagogastric junction. A stapler is passed just distal to the esophagogastric junction, dividing the stomach to leave a small gastric remnant at the distal end of the esophagus. Illustration by Corinne Sandone, Johns Hopkins University. Reprinted with permission.

peritoneal attachments to the most lateral aspect of the first and second portions of the duodenum are incised, and the duodenum and head of the pancreas are bluntly medialized.

Creation of the Neoesophagus

With the stomach completely mobilized, a site 6-cm proximal to the pylorus is identified on the lesser curvature, and the lesser omentum at that point is divided to the substance of the stomach in preparation for stapling. All attempts are made to spare the right gastric vessels. With the greater curvature retracted toward the left upper quadrant, the stomach is stapled longitudinally to create a conduit at least 5-cm wide (**Figure 5**). We use a 45-mm-long stapler with 3.5-mm staple depth (blue load) for the initial application. The cartridge side of the sta-

pler is used on the anterior surface of the stomach. After the initial firing, creation of the neoesophagus can be completed with 60-mm cartridges. Once completed, the distal margin on the specimen side is resected using a stapler and sent for frozen section examination.

Distal Esophageal Mobilization and Division of the Esophagogastric Junction

If there is a small hiatal opening, the right or left crural bundle is divided. The distal esophagus is circumferentially mobilized with its accompanying lymphatic tissue. All tissue should be mobilized away from the pericardium anteriorly, the right and left pleura laterally, and the surface of the aorta posteriorly. This dissection is carried as proximally as is safe.

The anatomical esophagogastric junction is identified with intraoperative upper endoscopy and divided with a thick-tissue endoscopic stapling device (**Figure 6**). The resultant specimen is retrieved at the conclusion of the case.

Exposure of the Cervical Esophagus

A 5-cm incision is made along the anterior border of the sternocleidomastoid. The subcutaneous tissue and platysma muscle are divided. The sternocleidomastoid is mobilized laterally. The omohyoid muscle is divided. The carotid sheath should be retracted laterally, and the fascia medial to the carotid artery is opened sharply along the length of the incision. The superior mediastinum should be easily accessed by placing a finger along the anterior spine and using blunt dissection to open this space. The lateral and posterior aspects of the esophagus are mobilized with blunt finger dissection.

Esophageal Inversion

A vein stripper is passed distally through a cervical esophagotomy until it is seen "bouncing" against the staple line. With the nasogastric tube withdrawn, a small gastrotomy is created at the staple line. The vein stripper is passed through this opening and withdrawn through the 12-mm right upper abdominal port site. A medium anvil is attached to the vein stripper. A 60-cm silk suture is tied to the end of the vein stripper. The vein stripper is withdrawn into the peritoneal cavity. The staple line and enterotomy site are reinforced with a horizontal mattress suture. The vein stripper is withdrawn through the cervical esophagotomy, creating an outside-to-in inversion of the distal esophagus (**Figure 7**). The rolled edge of the esophagus is grasped, and mediastinal attachments are divided under direct vision. These points of attachment can be accentuated by subtly moving the vein stripper in and out (**Figure 8**). Lymphatics are included within the inversion. Blunt transcervical finger dissection is used to complete the inversion (**Figure 9**). The esophagus is divided at the site of the cervical esophagotomy. The proximal margin of the esophagus is sent for intraoperative histologic examination.

Pull-up of the Neoesophagus and Esophagogastrostomy

A clamped-off 26F thoracostomy tube is attached to the silk suture brought up in the inversion. The chest tube is guided into the posterior mediastinum as the surgeon pulls on the silk suture from below. The tip of the neoesophagus is sutured to the end of the chest tube. After proper orientation of the neoesophagus is verified, the chest tube is gently withdrawn (**Figure 10**). Once the neoesophagus is palpated within the

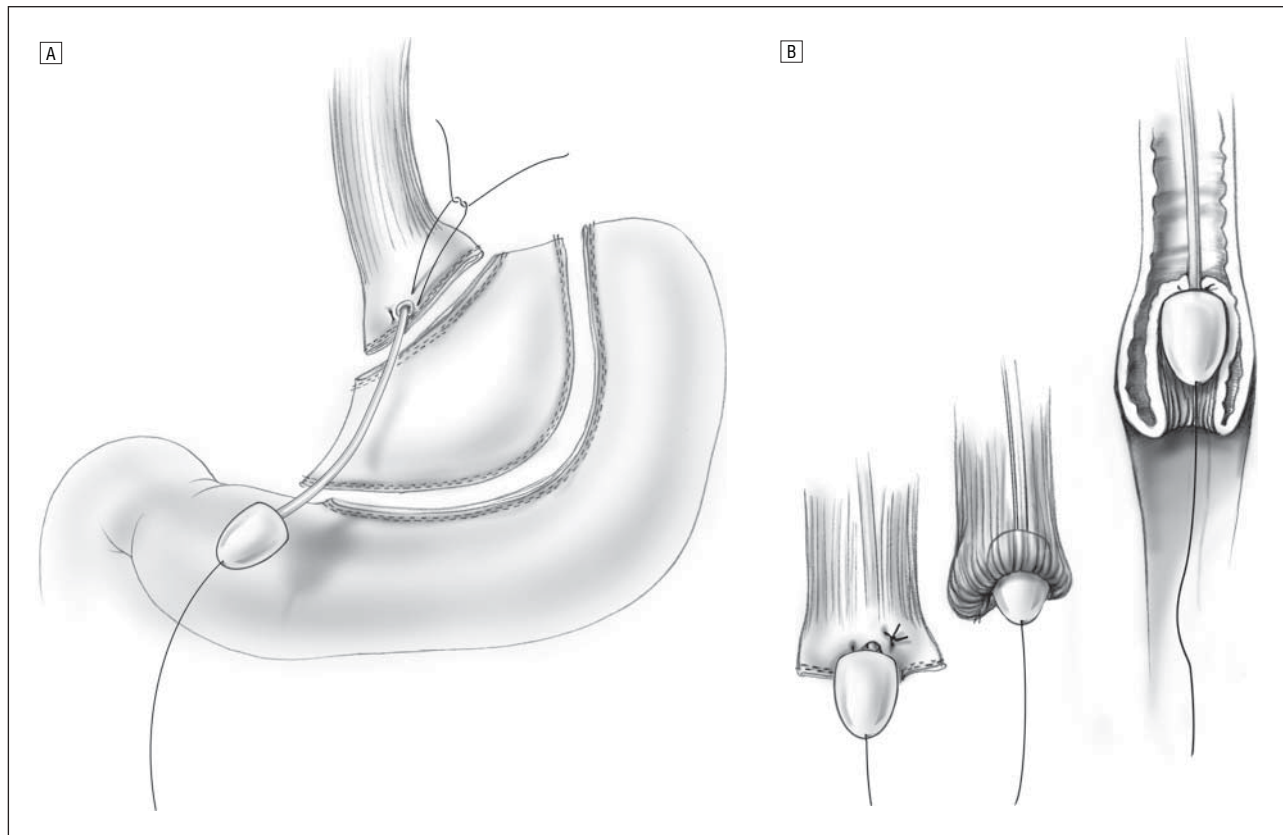


Figure 7. Esophageal inversion. A, The vein stripper exits through a small enterotomy in the gastric stump, buttressed by a horizontal mattress suture. Note the suture exiting from the bullet. This will be important in identifying the native anatomical space of the esophagus. B, The stripper is then pulled cephalad, inverting the esophagus. Illustration by Corinne Sandone, Johns Hopkins University. Reprinted with permission.

superior mediastinum, it is gently pulled into the cervical wound. A jejunostomy feeding tube is placed in select cases, depending on the patient's diagnosis and preoperative nutritional status.

We perform a stapled, end-to-side cervical anastomosis as described by Orringer et al.¹¹ The staple line of the lesser curvature resection site is rotated posteriorly. The neoesophagus is elevated to the skin level using a traction suture placed at the inferior aspect of the cervical incision. A gastrotomy is created in the vertical direction. A 3.5-mm stapling device is introduced into the esophagus and gastrotomy and fired, thereby creating an end-to-side anastomosis. A nasogastric tube is then carefully passed into the conduit. The remaining enterotomy is closed in 2 layers. A closed-suction drain is placed alongside the anastomosis, ensuring that the suction holes are not directly over the suture line. The abdomen is inspected and the lesser curvature resection specimen is removed in a plastic bag.

RESULTS

There were 19 men and 1 woman with a median age of 64 years (interquartile range [IQR], 59-72 years) in this series. The median body mass index was 29 (calculated as weight in kilograms divided by height in meters squared) (IQR, 25-32). Eighty percent of the patients had a diagnosis of high-grade dysplasia. In cases where stage I cancer was diagnosed preoperatively and only high-grade dys-

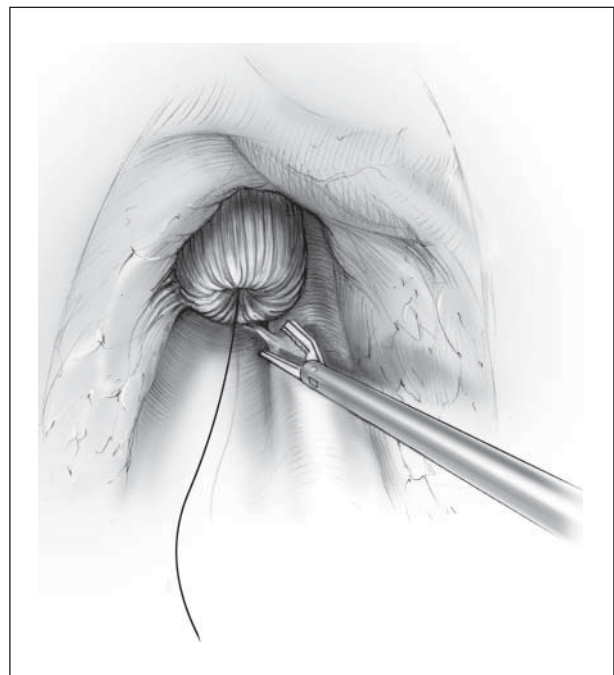


Figure 8. Division of the mediastinal attachments. A small posterior attachment is tented up the inversion and can be divided under direct vision. Illustration by Corinne Sandone, Johns Hopkins University. Reprinted with permission.

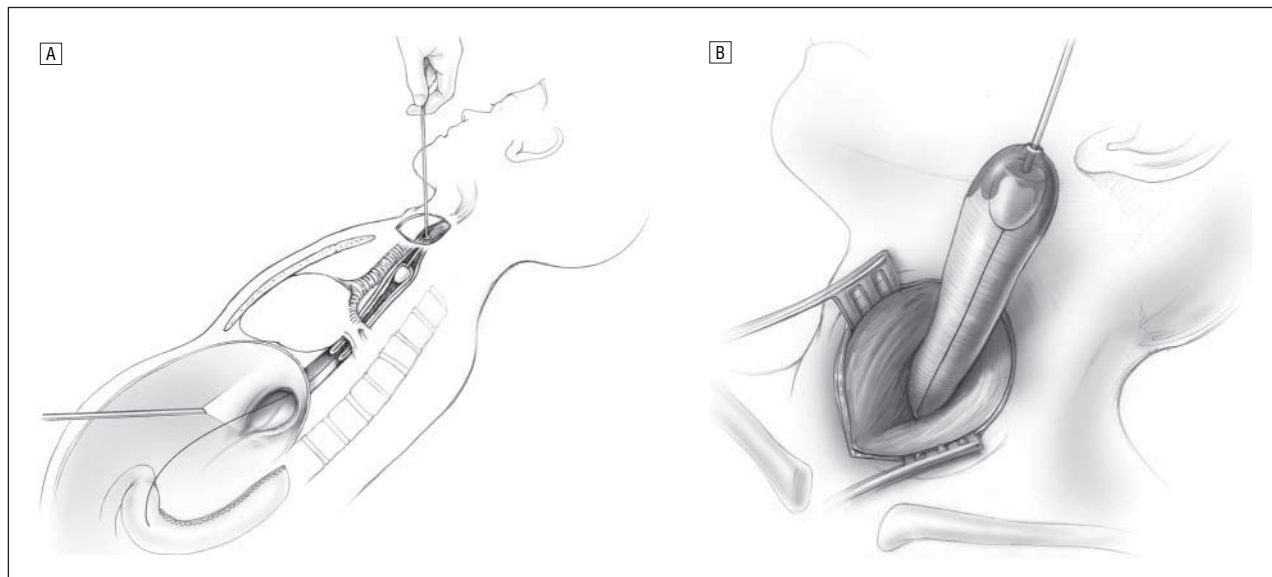


Figure 9. Course of esophageal inversion. A, Sagittal section showing the course of the esophageal inversion. B, Inverted esophagus as it is delivered through the cervical incision. Illustration by Corinne Sandone, Johns Hopkins University. Reprinted with permission.

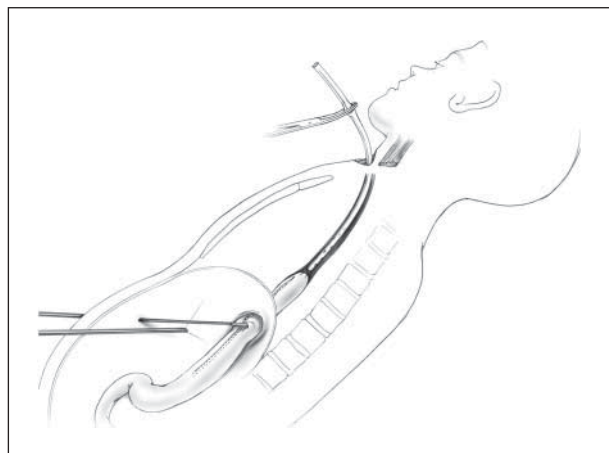


Figure 10. Pull-up of the gastric conduit. A chest tube has been passed through the cervical incision into the abdominal cavity under the guidance of a suture left in the course of the esophageal inversion. The gastric conduit, attached to the chest tube, is then guided through the mediastinum as the chest tube is gently pulled through the cervical incision. Illustration by Corinne Sandone, Johns Hopkins University. Reprinted with permission.

plasia was discovered after resection, patients had either undergone endoscopic mucosal resection of a nodule within a field of Barrett esophagus or clinical staging was based on the endosonographic appearance of a distinct lesion or fullness in the distal esophagus. Two patients had frankly invasive cancer, being stage II or greater. One of these patients, with a poor functional status, underwent induction therapy for stage IIb disease to control hemorrhage from an ulcerated tumor base. There was 1 patient with a preoperative diagnosis of long-segment Barrett esophagus and high-grade dysplasia who had unidentified stage I cancer secondary to sampling error.

There was 1 conversion to an open procedure. This patient had significant kyphosis, which precluded a safe laparoscopic mediastinal dissection with inversion. The median operative time was 448 minutes (IQR, 387-503 minutes), and median blood loss was 175 cm³ (IQR, 100-

Table. Major and Minor Complications

	No. (%)
Minor complication	
Atrial flutter	1 (5)
Atelectasis	5 (25)
Pleural effusion	3 (15)
Atrial fibrillation	3 (15)
Major complication	
Stricture requiring dilation	5 (25)
Vocal cord injury	2 (10)
Respiratory failure	2 (10)
Chylothorax	1 (5)
Empyema	2 (10)
Anastomotic leak	4 (20)

250 cm³). The median intensive care unit stay was 4 days (IQR, 2-13 days) and the median hospital stay was 9 days (IQR, 8-22 days). Fifty-five percent of patients had a jejunostomy feeding tube placed.

Overall, the anastomotic leak rate was 20% (4/20) (**Table**). Leaks were all managed with transcervical drainage, supportive care, and nutritional support. Twenty-five percent of patients developed an anastomotic stricture, all of which were successfully managed with endoscopic dilation. Two patients with stricture did not have a recognized anastomotic leak. The majority of complications were pulmonary, such as pleural effusion and atelectasis. Two patients developed early postoperative respiratory failure and required reintubation and ventilator support perioperatively. Ten percent (2/20) of patients sustained a unilateral vocal cord paralysis, which resolved with conservative management.

There was no in-hospital mortality. At 17 months' follow-up, 2 patients had died. One patient died of metastatic disease secondary to esophageal adenocarcinoma. The other patient died at home of complications related to severe sleep apnea approximately 2 weeks after operation.

End points were compared between the initial consecutive 10 cases (group 1) and the last 10 procedures (group 2). The incidence of anastomotic leak and stricture formation decreased from 30% to 10% and 40% to 10%, respectively, between the first 10 consecutive cases and the last 10 procedures. In addition, the number of lymph nodes procured with inversion increased 9-fold in group 2 when compared with group 1. There was a dramatic decrease in the duration of intensive care unit stay between groups (8.00 days [IQR, 1.75-20.25 days] vs 2.50 days [IQR, 2.00-6.75 days]). There was no difference in operative time or blood loss between the first and last 10 cases. There were no recurrent laryngeal nerve injuries in group 2.

Several procedural modifications took place during the evolution of this procedure (between groups 1 and 2) that we feel have both simplified the technique and improved outcomes:

1. We changed from a nasogastric tube to a vein stripper for esophageal inversion. In the first 6 cases, we stapled across the nasogastric tube at the time of esophagogastric junction division and used this for the inversion. It was discovered that this approach was less secure and more likely to pull free during inversion, especially if stripping of the proximal esophagus was required. Nasogastric tubes pulled free on 2 patients using this approach. Since changing to the vein stripper with a securing stitch, we have had no dislodgements during inversion (14 cases).

2. During the first 10 cases, we were performing a hand-sewn anastomosis in either 1 or 2 layers. In addition, the conduit was being tubularized to 3 cm in width. We feel that these 2 factors led to more pronounced ischemia at the tip of the fundus and an increase in anastomotic dehiscence. Since increasing conduit width to 5 cm and changing to an end-to-side, stapled esophagogastric anastomosis, our leak and stricture rates have dropped into an acceptable range.

3. Initially, the degree of lymphadenectomy was very limited. Throughout this series, we have gained significant experience pertaining to the points of tension created by inversion and the most optimal point of tissue division so as to perform a wide mediastinal sweep of lymphatic tissue, which ultimately becomes incorporated into the specimen with the rolling of the esophagus. At the completion of the procedure, we now see exposed bilateral pleura, aorta, and anterior structures such as the pericardium, pulmonary veins, and membranous trachea.

4. In our first 10 cases, we created 2 recurrent nerve neuropathies with resultant unilateral vocal cord paralysis. This may have been related to the proximal stripping of the esophagus during inversion (now a rare event because of extensive mobilization of the cervical esophagus and comfort with high transhiatal dissection) or stretch placed on the nerve during cervical dissection and retraction. Because we eliminated anything other than finger retraction below the level of the platysma during the cervical dissection, there were no injuries in the last 12 consecutive cases.

5. In the first 5 cases, there were 2 occasions where the anatomical space was lost and blind passage of the chest tube from the neck proved to be very difficult. This can

occur in patients with a very small hiatal opening; tight posterior mediastinum, as seen in those who are obese; and spinal deformities and when there is compromise of the mediastinal pleura. It has been very easy and time-saving to maintain the anatomical space for gastric pull-up by attaching a heavy silk suture to end of the vein stripper during inversion.

COMMENT

The majority of patients who undergo esophagectomy do so for the management of esophageal adenocarcinoma. For many of these patients, their cancer diagnosis is advanced with significant preoperative malnutrition and stress. Esophagectomy, which involves both the thoracic and abdominal cavities, is not a trivial procedure. It carries a case mortality rate of 5% to 25% and a complication rate of approximately 30% for strictures, anastomotic leak, pulmonary complications, and conduit ischemia.¹² This, coupled with the lethality of the disease process, has led some nonsurgeons to steer patients away from operative therapy for advanced locoregional cancer, opting instead for radiochemotherapy alone. Similarly, there is a trend among some gastroenterologists to enroll their patients with Barrett esophagus and high-grade dysplasia into intensive endoscopic surveillance and refer for esophagectomy only when invasive cancer is discovered. Clearly, there is a need to improve the morbidity and mortality rates associated with esophagectomy.

The minimally invasive esophagectomy described in this article allows near-complete dissection of the thoracic esophagus with the inversion technique. Through a conventional transhiatal approach, the area posterior to the trachea near the carina, termed *no-man's-land*, is a very difficult region to negotiate safely, since the esophagus occupies a significant portion of the posterior mediastinal space and prevents optimal visualization of the esophageal attachments. In addition, inadequate space for traction and countertraction is available in the standard transhiatal method. These issues create technical challenges that have tempered the enthusiasm for performing esophagectomy using minimally invasive techniques.

Inversion of the esophagus during the dissection addresses the issues faced in the standard approach. The process of inverting and deverting the esophagus permits identification of the lateral attachments. The inverted edge of the esophagus then serves as a point that can be grasped to provide proper counter-tension for an optimal dissection. In addition, we have found that an aggressive lymphadenectomy can be performed using this approach by incorporating the periesophageal fat and lymphatic tissue into the inversion. The dramatic increase in work space enables for better triangulation between the laparoscope and surgeon's instruments so that dissection is routinely carried up to the thoracic inlet, thereby avoiding the need to strip the esophagus.

In this series of patients, the operative technique evolved to optimize the technical reliability of the procedure. Early in the experience, inversion of the esophagus was achieved by stapling a nasogastric tube at the esophagogastric junction staple line. On occasion, how-

ever, the tube separated from the staple line. When this occurs, subsequent inversion of the esophagus is particularly difficult because of the retraction of the esophagus into the chest and compromised integrity of the tissue anchoring the nasogastric tube. The vein stripper was used to address this concern. Early experience with the vein stripper demonstrated the importance of ensuring that it exit through the center of the gastric stump. In this way, equal tension was available circumferentially, allowing an inversion effect rather than an "accordion" effect secondary to noninversion. Using the vein stripper also allowed for a smaller enterotomy secured by a purse-string suture, greatly increasing the structural strength of the anchor point and allowing more force to be applied to the inversion process in the final portion of the dissection. To date, this adaptation has resulted in no failures of the inversion tool pulling free from the distal esophagus.

Another adaptation was the use of silk suture to guide the placement of the gastric conduit after the esophagus has been fully dissected from its mediastinal attachments. In the early experience, a chest tube was blindly introduced through the posterior mediastinum and passed into the abdominal cavity, occasionally meeting resistance due to the creation of a false passage or tracking into the right chest. A silk suture trailing the vein stripper preserves the anatomical space as the esophagus is mobilized. After the dissection, the chest tube is tied to the proximal end of the suture and introduced through the cervical incision into the abdominal cavity, where the tip of the gastric conduit is sutured to the tube. The chest tube can then be withdrawn to guide the conduit into proper position.

Initially, esophagogastric anastomosis was performed using an end-to-end, hand-sewn technique. Among these patients, no difference in the incidence of anastomotic leaks was observed between those undergoing 1-layer anastomosis and those with a 2-layer anastomosis. The latter group of patients underwent the anastomosis with a linear stapled technique and developed a much lower leak rate. The improved outcomes may be attributed to the improved perfusion of the gastric conduit along the greater curvature, where the stapled anastomosis is performed. In contrast, the tip of the gastric conduit, where the hand-sewn anastomosis is performed, is the most ischemic portion of the gastric tube.^{11,13}

Intraoperative endoscopy is a critical component of the operation. It is initially performed to rule out a tumor at the cardia and to confirm the exact location of the anatomical esophagogastric junction.

Having created a 5-cm gastric tube in each of the patients, we did not perform a pyloroplasty. No patient developed complications related to gastric outlet obstruction. While a drainage procedure has been reported to improve early motility,^{14,15} it increases the complexity of the procedure, creates more bile reflux, and lengthens the operation.

These outcomes are comparable with those described in other published case series. It is useful to compare these results with other small series of minimally invasive esophagectomy reported in the literature. In 1 early report from the United States, 9 patients under-

went minimally invasive esophagectomy, predominantly via a transhiatal approach with cervical anastomosis.⁸ In that case series, the mean operative time was 6.5 hours, and no patient developed an anastomotic leak. A recent increased interest in minimally invasive transhiatal esophagectomy is evidenced by 3 reports similar to ours but using conventional transhiatal dissection techniques. In the first study, 22 patients underwent laparoscopic transhiatal esophagectomy. The average operative time was 380 minutes and 4.5% developed leaks.⁵ In the second trial, 20 patients underwent laparoscopic transhiatal esophagectomy, including 2 conversions to open procedures. Median operative time in this series was 415 minutes.⁶ In a third series of 25 patients undergoing minimally invasive esophagectomy, the reported leak rate was 12% with a mean operative time of 350 minutes.⁷ While these operative times are all less than that reported in our series, recent efficiencies lead us to believe that the LIE will be a 4- to 6-hour operation in a teaching setting and a bit faster than that when learners are not included. During the first 10 procedures, additional time was required because intraoperative procedure modifications were required. In the second 10 procedures, the involvement of learners slowed the conduct of the operation. In most of the last 10 cases, the primary surgeon was a laparoscopic fellow or chief resident in general surgery, hence, the longer operative times.

The LIE is a safe and feasible operation that shows tremendous promise in the treatment of benign and malignant esophageal disease. The hallmark of this procedure is the inversion of the esophagus, a maneuver that facilitates thoracic esophageal dissection and allows increased work space of the posterior mediastinum. With this technique, critical structures such as the membranous trachea, inferior pulmonary veins, and aorta are more easily identified and avoided. Although this procedure requires advanced laparoscopic skills, a dedicated operative team, and a critical care staff familiar with the care of these patients, it bears the potential to reduce the barrier to adopting a minimally invasive approach to esophagectomy when performed by the right surgical team in the right setting.

Accepted for Publication: May 3, 2006.

Correspondence: Blair A. Jobe, MD, Portland VA Medical Center, Surgical Service P3GS, PO Box 1034, Portland, OR 97207 (jobeb@ohsu.edu).

Funding/Support: This work was supported in part by National Institutes of Health grant K23 DK066165-01 (Dr Jobe).

Previous Presentation: This paper was presented at the 77th Annual Meeting of the Pacific Coast Surgical Association; February 18, 2006; San Francisco, Calif; and is published after peer review and revision. The discussions that follow this article are based on the originally submitted manuscript and not the revised manuscript.

REFERENCES

1. DePaula AL, Hashiba K, Ferreira EA, de Paula RA, Grecco E. Laparoscopic transhiatal esophagectomy with esophagogastroplasty. *Surg Laparosc Endosc*. 1995;5:1-5.

2. Kim CY, Diggs B, Deveney C, et al. Trends in the management of esophageal carcinoma: treatment practices of 618 esophageal surgeons. Paper and poster presented at: 45th Annual Meeting of the Society for Surgery of the Alimentary Tract; May 2004; New Orleans, La.
3. Luketich JD, Alvelo-Rivera M, Buenaventura PO, et al. Minimally invasive esophagectomy: outcomes in 222 patients. *Ann Surg*. 2003;238:486-494, discussion 494-495.
4. Luketich JD, Nguyen NT, Weigel T, et al. Minimally invasive approach to esophagectomy. *JSLs*. 1998;2:243-247.
5. Avital S, Zundel N, Szomstein S, Rosenthal R. Laparoscopic transhiatal esophagectomy for esophageal cancer. *Am J Surg*. 2005;190:69-74.
6. Bann S, Moorthy K, Shaul T, Foley R. Laparoscopic transhiatal surgery of the esophagus. *JSLs*. 2005;9:376-381.
7. Collins G, Johnson E, Kroshus T, et al. Experience with minimally invasive esophagectomy. *Surg Endosc*. 2006;20:298-301.
8. Swanstrom LL, Hansen P. Laparoscopic total esophagectomy. *Arch Surg*. 1997;132:943-947, discussion 947-949.
9. Jobe BA, Reavis KM, Davis JJ, Hunter JG. Laparoscopic inversion esophagectomy: simplifying a daunting operation. *Dis Esophagus*. 2004;17:95-97.
10. Akiyama H, Tsurumaru M, Ono Y, Udagawa H, Kajiyama Y. Esophagectomy without thoracotomy with vagal preservation. *J Am Coll Surg*. 1994;178:83-85.
11. Orringer MB, Marshall B, Iannettoni MD. Eliminating the cervical esophagogastric anastomotic leak with a side-to-side stapled anastomosis. *J Thorac Cardiovasc Surg*. 2000;119:277-288.
12. Briel JW, Tamhankar AP, Hagen JA, et al. Prevalence and risk factors for ischemia, leak, and stricture of esophageal anastomosis: gastric pull-up versus colon interposition. *J Am Coll Surg*. 2004;198:536-541, discussion 541-542.
13. Ercan S, Rice TW, Murtthy SC, Rybicki LA, Blackstone EH. Does esophagogastric anastomotic technique influence the outcome of patients with esophageal cancer? *J Thorac Cardiovasc Surg*. 2005;129:623-631.
14. Law S, Cheung MC, Fok M, Chu KM, Wong J. Pyloroplasty and pyloromyotomy in gastric replacement of the esophagus after esophagectomy: a randomized controlled trial. *J Am Coll Surg*. 1997;184:630-636.
15. Urschel JD, Blewett CJ, Young JE, Miller JD, Bennett WF. Pyloric drainage (pyloroplasty) or no drainage in gastric reconstruction after esophagectomy: a meta-analysis of randomized controlled trials. *Dig Surg*. 2002;19:160-164.

DISCUSSION

Marco G. Patti, MD, San Francisco, Calif (presented by Dr Sherry M. Wren): Dr Patti, unfortunately, has a family emergency, and he asked me to read his comments. I think he picked me because I am half Sicilian and have curly hair, like him. So, these are his comments, and I will add my own at the end.

"I think that this was a very interesting presentation. The manuscript that Dr Jobe kindly sent me a few days ago is well written and the technique is well illustrated. The authors have already provided major contributions to the minimally invasive treatment of benign esophageal disorders such as GERD [gastroesophageal reflux disease] and achalasia, and today they have presented their experience with a minimally invasive esophagectomy for high-grade dysplasia and cancer. The goal is to reduce the morbidity of the operation, the ICU [intensive care unit] and total length of hospital stay as compared to the open technique. If I can summarize their data, it seems that:

- Fifty percent of patients had respiratory complications.
- Twenty percent of patients had cardiac complications.
- Twenty percent had an anastomotic leak.
- Ten percent had any empyema.
- Ten percent had damage to the recurrent laryngeal nerve.
- Five percent had a chylothorax.
- Overall, 50% of patients spent an average of 13 days in the ICU.
- Sixteen of 20 patients were operated for high-grade dysplasia, but cancer was found in 1 specimen only (6%).

I have 3 questions for the authors: (1) How do you compare these results with the results obtained in your center with a classic open approach, either transhiatal or transthoracic. (2) Where do you plan to go from here, and what is your advice for the surgeons in the audience who perform esopha-

gectomies for cancer. Should we abandon the classic approach and embrace this new technique? (3) Finally, the rationale to perform an esophagectomy in patients with high-grade dysplasia is that cancer is found in about 33% of the specimens. In this series, however, it was found in 6% only, which means that 94% of the patients had an esophagectomy when cancer was not present. Based on these data, do you still advise such an aggressive approach?"

Sherry M. Wren, MD, Palo Alto, Calif: Your video would seem to demonstrate violation of the basic oncologic principle for en bloc dissection. You are directly opening the esophagus over the cancer to place the vein stripper, which could then contaminate the posterior mediastinum with cancer cells as you invert the esophagus back to the neck. What are your thoughts on that?

Luther Cobb, MD, Arcata, Calif: I was wondering if any of these are applicable to the presence of a bulky malignancy and whether you are spilling cells in the mediastinum in that circumstance. Second, do you have any comments about recently developed techniques for robotic transthoracic port surgery in these circumstances? Do you have any follow-up about mediastinal tumor recurrences?

I. Benjamin Paz, MD, Duarte, Calif: As we move from open surgery to minimally invasive surgery, I cannot but think on how to establish that we have achieved our objectives. In colon surgery, we tried to establish certain standards. We measure the colon specimen length and establish the number of lymph nodes in the specimen in order to feel that we have accomplished adequate oncological outcomes. In this case, I feel that you have only proved that the procedure can be done laparoscopically, but you have not shown that you have achieved the same oncological outcomes, which ultimately is the objective of this operation. With probably 30% to 50% of these patients sometimes harboring an invasive cancer, I think we should maintain oncological standards.

What are the true indications for this procedure? In your manuscript, you indicate that some of the patients have early carcinomas. Do you feel that that is an adequate indication? Second, are any of these patients receiving preoperative treatment? Third, in order to do a study, as you suggested at the end of your presentation, what should be the outcomes that we should be measuring to compare open procedures vs laparoscopic or robotic procedures.

At our institution we have adopted robotics because we felt that we could do the same procedure as open and accomplish the same abdominal and mediastinal lymph node dissection.

Dr Hunter: Dr Patti, via Dr Wren, asked 3 questions. The first was to compare laparoscopic inversion esophagectomy (LIE) with open procedures. This report is primarily a descriptive analysis of a single set of patients and wasn't intended to provide comparisons with open esophagectomy. Having said that, we couldn't help but make sure this new procedure was not more morbid than open esophagectomy. Our complication rate across the whole series was about equivalent with our open esophagectomy experience. Forty percent of patients had at least 1 significant complication. This number is equivalent to the complication rate reported in most large series of open esophagectomy. There was no in-hospital mortality, and the complication rate decreased in the second 10 patients reported in this cohort. Clearly, this experience describes our learning curve. In many ways this report is similar to a report from a decade ago with the development of the laparoscopic paraesophageal hernia in which there was a great deal of initial concern that our complication rates were high, though no higher than the open repair. Now, laparoscopic paraesophageal hernia repair is the standard to which all other approaches are compared.

The most dramatic benefits of the LIE are the diminished postoperative pain and the more rapid recovery. Our length of

stay was about half of that that we saw with open esophagectomy, and epidural analgesia was unnecessary. As we started to apply this technique we were very selective about its use; only 20 patients over 3 years underwent LIE. This is about a quarter of our esophagectomy experience. Most patients with stage II or III cancer and most patients who had had a previous laparotomy were approached with other techniques at our institution during this time period, allowing us the opportunity for side-by-side comparison. As compared to open transhiatal esophagectomy (THE), most LIE patients were out of bed walking the day after surgery. In fact, they are usually fully ambulatory within a few days of LIE but are kept in the hospital waiting for their postoperative contrast swallow on postoperative day 6 or 7, as has been our custom following open surgery.

Who should have this operation? We made a conscious decision at the beginning of this experience to operate only patients with high-grade dysplasia and small nodular intramucosal cancers, some of which were resected, with positive margins, using endoscopic mucosal resection (EMR). Endoscopic ultrasound (EUS) staging suggested these were all T1a tumors or less, in which the lamina propria appeared clinically to be intact, a stage not associated with lymph node metastases.

Subsequently, we discovered that we could achieve a wide lower mediastinal and upper abdominal lymph node clearance with this technique, equivalent or better than we were achieving with a standard THE. This allowed us to extend our indications for LIE to include cancers that we would approach with THE. When necessary to preserve the integrity of the gastroesophageal junction, such as in patients with GE [gastroesophageal] junction malignancy following a complete or near-

complete response to neoadjuvant therapy, we have performed an antegrade inversion, where the long tongue of the lesser curvature (following tube construction) is brought out a port site and the inversion starts at the neck, with the specimen removed through the widened port site.

Why so much high-grade dysplasia in this series? Using aggressive biopsy techniques and the improved ability of endoscopic and ultrasonographic imaging to identify early cancers, the frequency with which unsuspected cancer was discovered in the pathology specimen decreased, as compared to previous reports. The addition of EMR to the diagnostic “quiver” allowed the detection of cancer in nodules where preoperative biopsy only showed HGD [high-grade dysplasia]. While these advances in preoperative cancer diagnosis may decrease the rate of unsuspected cancer detection in the pathology specimen, the natural history of HGD progressing to invasive cancer in the majority of patients remains the most compelling reason to perform esophagectomy early in an otherwise healthy patient with HGD. The risk of following patients with HGD and only referring when cancer is detected is that all series which have employed this strategy have reported at least 1 patient with advanced cancer detected during the esophagectomy, leading to cancer-related death. Surveillance is supposed to prevent this, so the best time to intervene aggressively remains the point at which HGD is detected until more sophisticated diagnostic techniques can drive the rate of unsuspected cancer detection to nil.

Bulky malignancies have not been done with an MIS [minimally invasive surgical] technique in our hands, and we have not used the DaVinci robot for esophagectomy. I am not aware of any data showing robotics to be of any advantage in upper abdominal minimally invasive surgery.