

Laparoscopic gastrectomy with regional lymph node dissection for upper gastric cancer

S. Tanimura¹, M. Higashino¹, Y. Fukunaga¹, S. Kishida¹, A. Ogata¹, Y. Fujiwara¹ and H. Osugi²

Departments of Gastroenterological Surgery, ¹Osaka City General Hospital and ²Osaka City University School of Medicine, Osaka, Japan

Correspondence to: Dr S. Tanimura, Department of Gastroenterological Surgery, Osaka City General Hospital, 2-13-22 Miyakojimahondori, Miyakjima-ku, Osaka 534-0021, Japan (e-mail: stoghjpn@aol.com)

Background: The technique and results of laparoscopic gastrectomy in 110 patients with gastric cancer located in the upper third of the stomach are presented.

Methods: Proximal gastrectomy was performed for lesions in the upper third of the stomach, and total gastrectomy for those that spread over both the upper and middle third. D1 and D2 lymph node dissection was undertaken in patients with T1 or T2 lesions. Anastomosis of the oesophagus was performed intracorporeally using a conventional circular stapling device or a laparoscopic linear stapler.

Results: Median operating time was 247 min for proximal gastrectomy and 285 min for total gastrectomy; median blood loss was 207 and 334 ml respectively. A median of 23 lymph nodes was harvested from patients in the proximal gastrectomy group and 34 from those having a total gastrectomy. There was minimal morbidity and fast recovery after surgery. Postoperative recurrence occurred in only one patient, giving a recurrence rate of 0.9 per cent.

Conclusion: Laparoscopic gastrectomy for upper gastric cancer appears to be a safe and curative procedure.

Paper accepted 4 October 2006

Published online 23 October 2006 in Wiley InterScience (www.bjs.co.uk). DOI: 10.1002/bjs.5542

Introduction

Laparoscopic gastrectomy for gastric cancer has become more common as a result of advances in surgical technique. Following a previous report of laparoscopic distal gastrectomy with regional lymph node dissection for tumours of the middle and lower third of the stomach^{1,2}, the authors present the procedure and results of laparoscopic surgery for gastric cancer located in the upper portion of the stomach.

Patients and methods

From March 1998 to January 2006, 539 patients with gastric cancer underwent laparoscopic gastrectomy with regional lymph node dissection at Osaka City General Hospital. Laparoscopic resection was performed in 110 patients with upper gastric carcinoma between March 1999

and January 2006. None of the lesions was suitable for endoscopic mucosal resection. There was no evidence of lymph node metastasis on preoperative examination in any patient (tumour node metastasis (TNM) stage clinical T2 N0 or below).

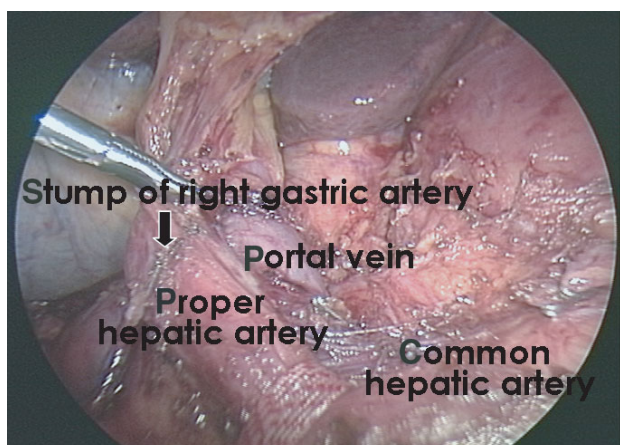
The surgical approach was as follows: 30 patients with a T1 lesion and 42 with a T2 lesion in both the upper and middle thirds underwent total gastrectomy with D1 and D2 dissection respectively, followed by Roux-en-Y reconstruction; 34 patients with a T1 lesion limited to the upper third had proximal gastrectomy with D1 dissection followed by oesophagogastronomy; and four patients with a T2 lesion limited to the upper third had proximal gastrectomy with D2 dissection followed by jejunal interposition.

Four 12-mm trocars were placed in the paraumbilical, bilateral abdominal and left hypochondral regions. Two 5-mm instruments were inserted from the epigastric and right hypochondral portions. The epigastric 5-mm port was extended to approximately 5 cm when extracting the specimen and performing the reconstruction. Stomach

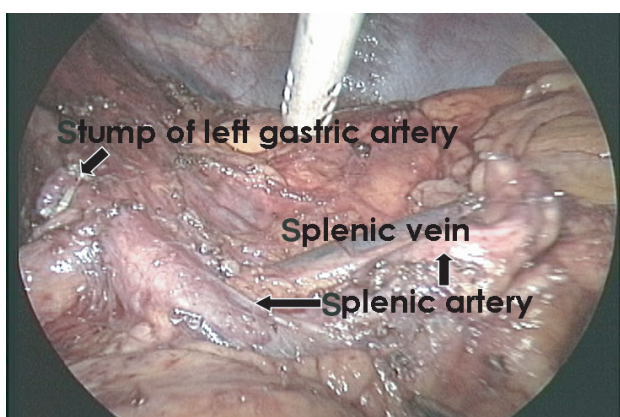
The Editors have satisfied themselves that all authors have contributed significantly to this publication

ablation and lymph node dissection were performed as for conventional open surgery. All lymph nodes in groups 1 and 2, as defined by the Japanese Classification of Gastric Carcinoma³, were excised during D2 dissection. Laparoscopic views around the hepatic and splenic arteries after lymph node dissection are shown in *Fig. 1*.

In 68 patients anastomosis of the oesophagus (oesophagojejunostomy or oesophagogastrostomy) was performed using a conventional circular stapling device (PCEEA[®] 25; US Surgical Corporation, Norwalk, Connecticut, USA). Insertion of the anvil of the device into the oesophagus was undertaken in 65 patients after performing a cigarette suture of the oesophageal stump with an Endo-Stitch[™] (US Surgical Corporation) (*Fig. 2*). However, in three patients oral insertion of the anvil guided by a nasogastric suction tube was performed, and oesophagojejunostomy using a double stapling technique was carried



a Hepatic artery



b Splenic artery

Fig. 1 Laparoscopic view around **a** the hepatic artery and **b** the splenic artery after lymph node dissection

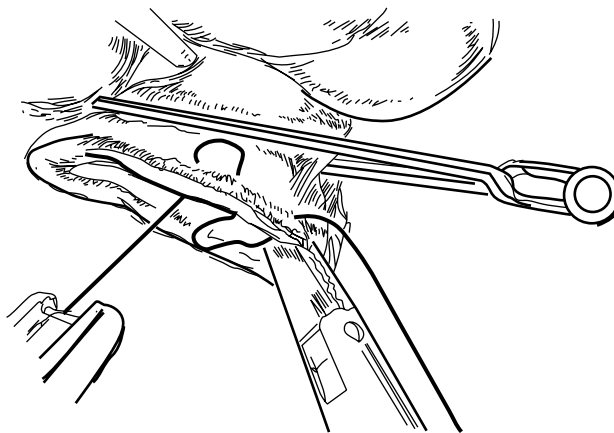
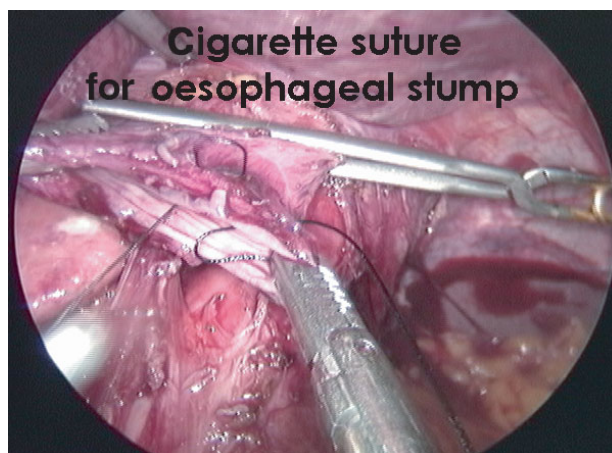

Fig. 2 Oesophagojejunostomy using a PCEEA[®] 25 circular stapling device

out owing to the relatively extensive tumour invasion into the oesophagus (*Fig. 3*).

In the remaining 42 patients, oesophagojejunostomy was performed by side-to-side anastomosis using a laparoscopic linear stapling device (Endoliner Cutter[®]; Ethicon, Cincinnati, Ohio, USA) (*Fig. 4*). After anastomosis, the common orifice was closed by using one or two firing series of the Endoliner Cutter or a handsewn method. Jejunogastrostomy and jejunojejunostomy were then performed in patients having interposition surgery, and jejunojejunostomy (for Roux-en-Y anastomosis) in those having a total gastrectomy, extracorporeally through the extended epigastric port.

Results

Median operating time was 247 (range 160–325) min for proximal gastrectomy and 285 (range 195–450) min

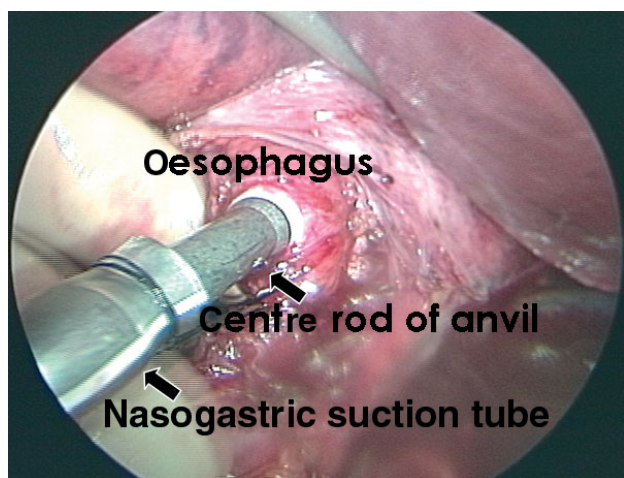


Fig. 3 Oesophagojejunostomy using a double-stapling technique with oral insertion of the anvil head

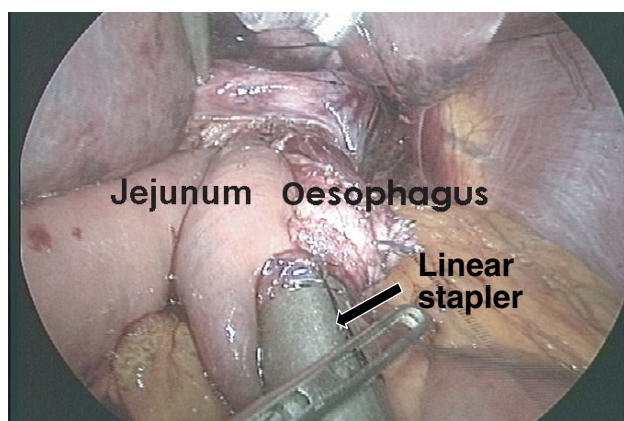


Fig. 4 Oesophagojejunostomy by means of side-to-side anastomosis using a linear stapler

for total gastrectomy; median blood loss was 207 (range 15–600) and 334 (range 26–1300) ml respectively. With regard to the learning curve, the median operating time for the first and last ten proximal gastrectomies was 261 and 238 min respectively, and that for the first and last 20 total gastrectomies was 311 and 260 min. A median of 23 (range 8–45) lymph nodes was harvested in the proximal gastrectomy group, and 34 (range 5–71) in the total gastrectomy group. After proximal gastrectomy the median (range) time to passing gas, oral feeding and discharge from hospital was 3.0 (2–4), 4.4 (3–6) and 13.9 (7–24) days respectively, compared with 2.9 (1–5), 4.7 (3–8) and 15.4 (9–25) days following total gastrectomy. Postoperative complications involved minor leakage in two patients in the proximal gastrectomy group

Table 1 Histopathological findings

	Proximal gastrectomy (n = 38)	Total gastrectomy (n = 72)
Histological type		
Papillary	0 (0)	8 (11)
Well differentiated	18 (47)	6 (8)
Moderately differentiated	10 (26)	26 (36)
Poorly differentiated	10 (26)	32 (44)
Depth of tumour invasion		
Mucosa	9 (24)	14 (19)
Submucosa	22 (58)	26 (36)
Muscularis propria	5 (13)	9 (13)
Subserosa	2 (5)	23 (32)
Lymph node metastasis		
Negative	35 (92)	56 (78)
Positive		
Group 1 nodes	2 (5)	11 (15)
Group 2 nodes	1 (5)	5 (7)

Values in parentheses are percentages.

and one patient in the total gastrectomy group, and pancreatitis in one patient who had a total gastrectomy. All were treated conservatively with no need for further surgery.

Histological type, depth of tumour invasion and lymph node metastasis are shown in *Table 1*. The median length of follow-up was 2.5 (range 0.3–7.1) years. Recurrence occurred in one patient, diagnosed as hepatic metastasis 1 year after total gastrectomy, giving a recurrence rate for all patients of 0.9 per cent.

Discussion

Laparoscopically assisted distal gastrectomy has been performed recently for early gastric cancer^{4–6}. Few reports, however, have considered laparoscopic surgery for upper gastric tumours. Uyama *et al.*⁷ concluded that laparoscopic gastrectomy for advanced upper gastric cancer was feasible. In the present study laparoscopic surgery for upper gastric lesions was performed in a similar manner to conventional open gastrectomy. Using this procedure, lymph node dissection and reconstruction were seen to be adequate and as safe as when performed by a conventional open technique. The double stapling technique for oesophagojejunostomy by oral insertion of the anvil of the PCEEA guided by a nasogastric suction tube is useful for patients with a lesion that has invaded the oesophagus, as a sufficient proximal surgical margin can be achieved. Moreover, oesophagojejunostomy by side-to-side anastomosis using a laparoscopic linear stapling device is a simple and useful procedure to substitute for

an anastomotic technique using the PCEEA. Although this procedure should, if possible, be compared with open surgery in a randomized trial, the authors consider that laparoscopic gastrectomy for upper gastric cancer is feasible and safe.

In summary, laparoscopic gastrectomy with regional lymph node dissection for upper gastric cancer is considered to be a safe and curative procedure. An intracorporeal anastomotic technique using a conventional circular stapling device, as well as linear stapling devices, appears to be safe and reliable after laparoscopic gastrectomy for upper gastric tumours.

References

- 1 Tanimura S, Higashino M, Fukunaga Y, Osugi H. Hand-assisted laparoscopic distal gastrectomy with regional lymph node dissection for gastric cancer. *Surg Laparosc Endosc Percut Tech* 2001; **11**: 155–160.
- 2 Tanimura S, Higashino M, Fukunaga Y, Osugi H. Laparoscopic distal gastrectomy with regional lymph node dissection for gastric cancer. *Surg Endosc* 2003; **17**: 758–762.
- 3 Japanese Gastric Cancer Association. *Japanese Classification of Gastric Carcinoma* (13th edn). Kanehara: Tokyo, 1999.
- 4 Nagai Y, Tanimura H, Takifuji K, Kashiwagi H, Yamoto H, Nakatani Y. Laparoscope-assisted Billroth 1 gastrectomy. *Surg Laparosc Endosc* 1995; **5**: 281–287.
- 5 Kitano S, Shimoda K, Miyahara M, Shiraishi N, Bandoh T, Yoshida T *et al.* Laparoscopic approaches in the management of patients with early gastric carcinomas. *Surg Laparosc Endosc* 1995; **5**: 359–362.
- 6 Shiraishi N, Adachi Y, Kitano S, Bandoh T, Katsura T, Morimoto A. Indication for and outcome of laparoscopy-assisted Billroth 1 gastrectomy. *Br J Surg* 1999; **86**: 541–544.
- 7 Uyama I, Sugioka A, Fujita J, Komori Y, Matsui H, Hasumi A. Laparoscopic total gastrectomy with distal pancreateosplenectomy and D2 lymphadenectomy for advanced gastric cancer. *Gastric Cancer* 1999; **2**: 230–234.

50 years ago

Per-operative manometry and radiology in biliary tract disorders

One of the first clinical experiments published by BJS with an attempt to correlate anatomical appearances with functional disturbance. Readers might note the absence of ethical approval for a study not designed to specifically benefit the participants!

The purpose of this paper is to describe a technique of manometric and radiological control of biliary tract surgery to be carried out at the time of operation. The technique gives precise information on biliary tract function and more exact information on morphological change than is possible from visual and tactile examination or from instrumental probing of the tract, which can be dangerous. The technique is comparatively simple and does not prolong the operation for more than ten to fifteen minutes. During the last ten years the technique has undergone simplification and as far as possible all causes of error have been removed so that it is now possible to assess biliary tract function accurately and to demonstrate clearly morphological change.

Mallet-Guy P, Rose JD. Per-operative manometry and radiology in biliary tract disorders. *Br J Surg* 1956; **44**: 55–68 (DOI: 10.1002/bjs.18004418310)

All BJS articles from volume 1 issue 1 are now available online to eligible subscribers at www.bjs.co.uk